

# Four Sides of Coin

S. Thangavelu, S. Shanthi, V. Poovazhagi, P. Ramachandran, P. Jeyachandran

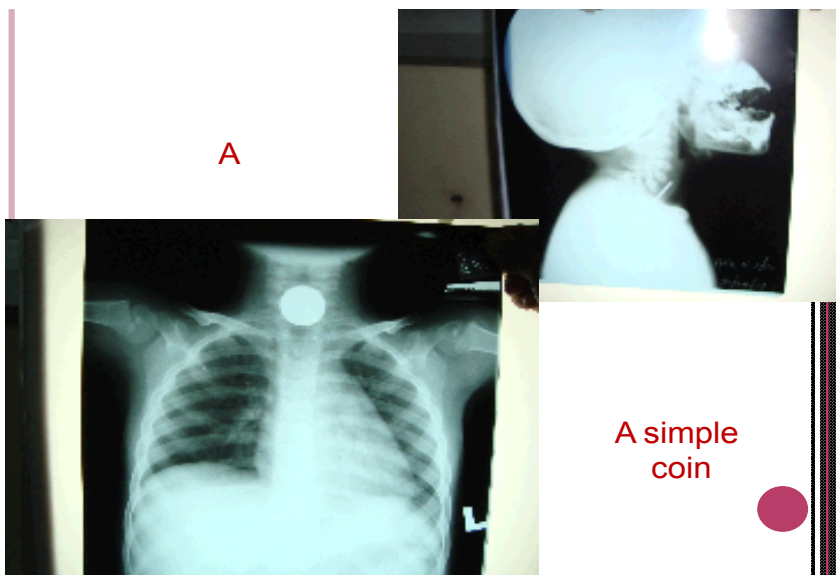
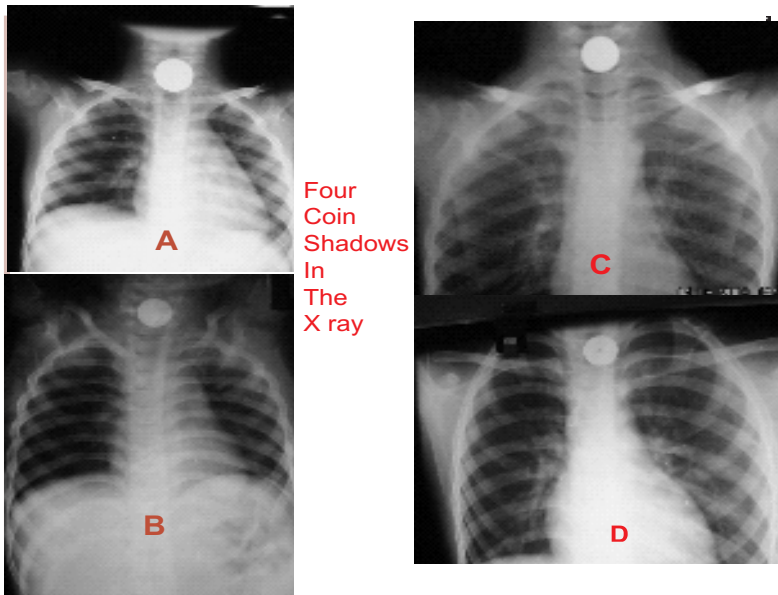
Department of Pediatrics and Pediatric Intensive Care

Institute of Child Health and Hospital for Children, Madras Medical College, Chennai- 600 008

Most of the coins have two sides, sometime four. We report about four children who have swallowed foreign bodies and presented with noisy breathing. Following are their chest x-rays.

noisy breathing. X-ray chest showed a coin shadow. Because it is lodged in cricopharynx, it is placed in frontal plane to show this view/ If the x-ray shows the edge of the coin, it means it is wedged in trachea in the sagittal plane.

A: This boy swallowed a coin and came with



A: This boy swallowed a coin and came with noisy breathing. X-ray chest showed a coin shadow. Because it is lodged in cricopharynx, it

is placed in frontal plane to show this view/ If the x-ray shows the edge of the coin, it means it is wedged in trachea in the sagittal plane.

Lateral picture confirmed that it is a simple coin, removed by ENT surgeon, and the patient was discharged uneventfully. This is a simple and quiet story

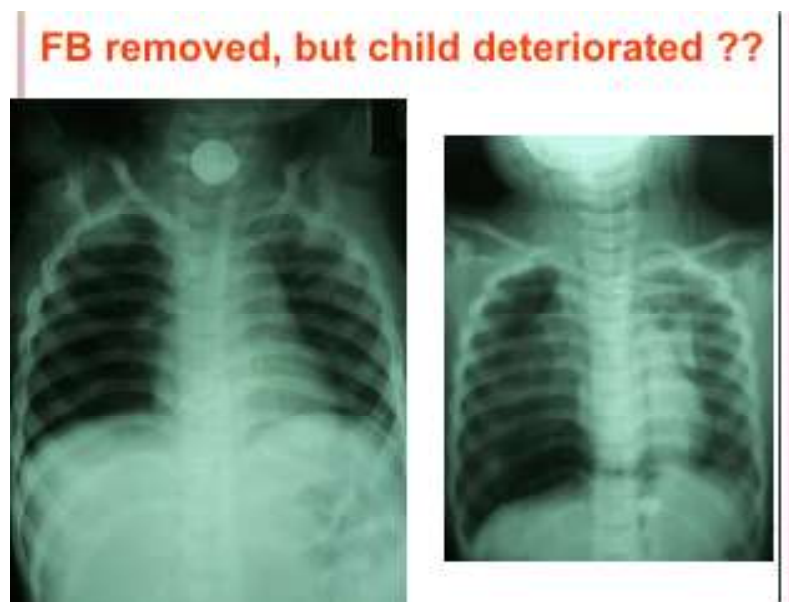B: Story of the child B was terrifying. This was a 3 years old girl with Down's syndrome brought by mother for drooling of saliva and noisy breathing. X-ray picture was a surprise for her, as she is not aware about the foreign body. Again same coin and the child has a mild distress and noisy breathing. SpO2 was normal in room air. ENT surgeon attempted removal in the emergency room, but failed. It was planned to remove the coin in operation theatre under general anesthesia. Unfortunately anesthetists

### Child B

were busy with multiple emergencies whole night, the procedure was postponed to next day as an elective procedure, as the child was relatively stable.

Question: Was it a right decision. If no, what is the objection to postponement?

About 11 hrs after admission, foreign body was removed under anesthesia without any difficulty. But the child deteriorated with worsening respiratory distress. She was shifted to Pediatric Intensive Care Unit. On arrival she had severe respiratory distress and desaturation. X-ray taken on arrival is this (Fig )



What is the x-ray finding?

It is air leak manifesting as subcutaneous emphysema, pneumomediastinum and right sided pneumothorax. Child was managed with, chest tube placement on the right side, then intubation and ventilatory support. In the next 2 hours she also developed pneumothorax on the left side and second intercostal drain was placed on the left side. Despite all the supportive management, child deteriorated and died.

Question: Why the child deteriorated. Coin did not have any sharp edge. As per the ENT surgeon, it was an easy intervention without any trauma.

A close look at the foreign body after cleaning well, revealed the truth. It was a button battery

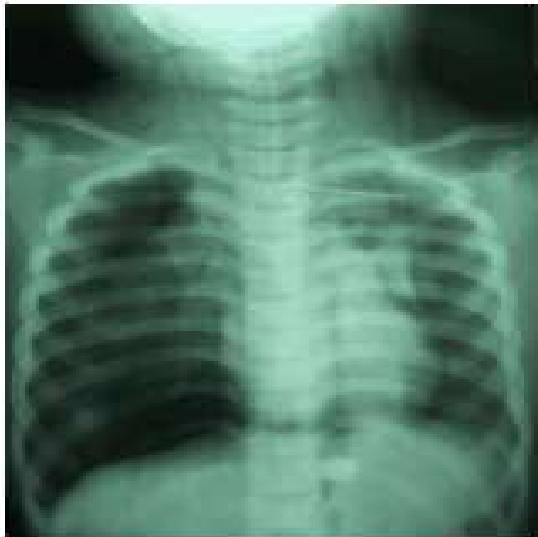and not a coin as believed. This was the first encounter with a button battery in the year 2001. Since then button battery continues to be a menace. It can cause corrosion by pressure necrosis, electrical discharge and more importantly leaking of the alkali leading to caustic burns.

Lesson learnt; In four sites a button battery should be removed immediately without any delay, if they are lodged in cricopharynx, esophagus, nose or ear. In these places necrosis can occur in a short period of time, even in 4-6 hours. Once they passed the esophagus, they are likely to pass out uneventfully.

Battery lodged in esophagus, is removed by fiberoptic endoscopy or by technique using foleys

catheter.

## SC Emphysema Pneumothorax

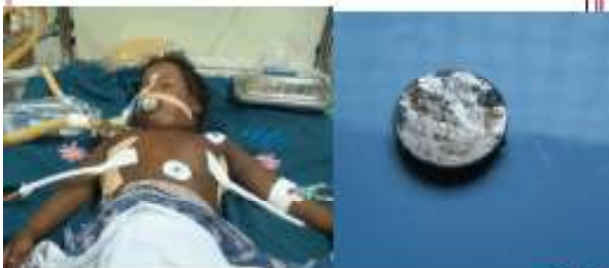

Battery expulsion should be confirmed by inspection of the stools and by x-ray abdomen. Whole bowel irrigation, cathartics and enema have been successfully used to evacuate the battery. Surgical intervention is very rarely (< 1% of the patients) needed ones it has gone beyond esophagus. It should

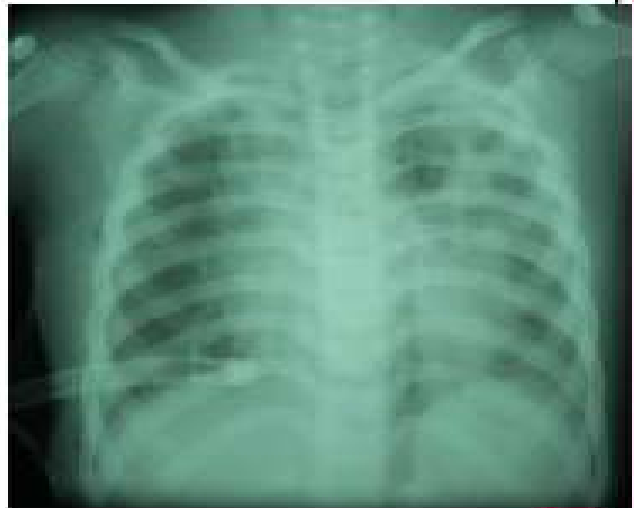be usually considered when there is recurrent vomiting, obstructive symptoms, abdominal pain and GI bleeding

Child B . . .

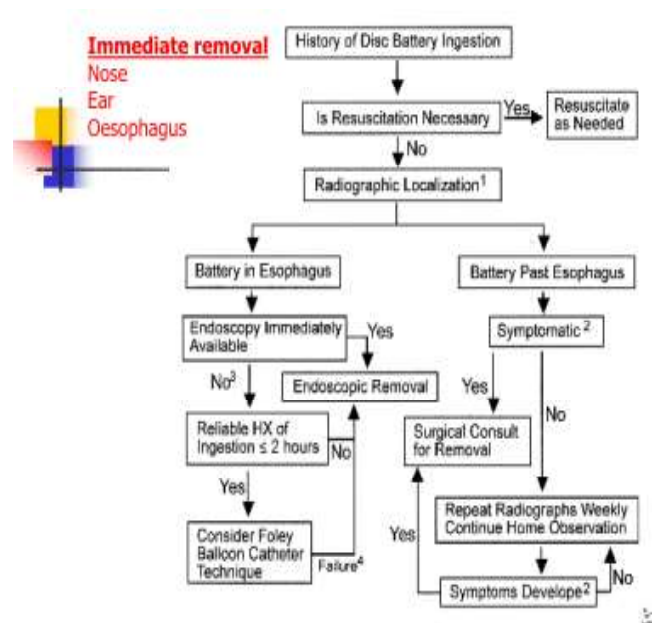
This is not coin  
Button Battery



## chest tube inserted



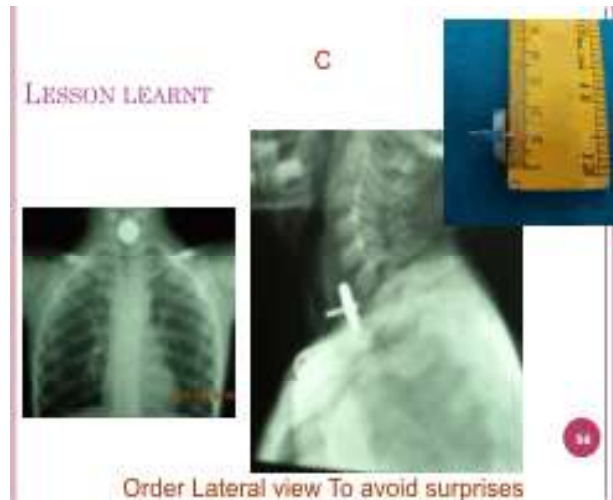
Inserted/ ingested/ inhaled button battery



C: This 10 years old boy was keeping a disc like pambaram (Top) while playing. Accidentally he swallowed and it got stuck in the throat. He was brought with mild breathlessness and subcutaneous emphysema, but no pneumothorax. Lateral x-ray revealed the full appearance of the foreign body

Question: What are the x-ray findings?

It was a disk with sharp, metallic axis found to be impacted in the cricopharynx, piercing the posterior aspect of trachea leading to airleak. He was kept under observation after removal of the foreign body which was bit difficult because of the piercing nature. He was discharged well.

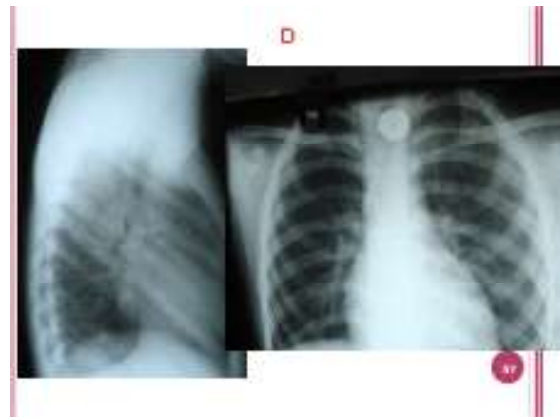
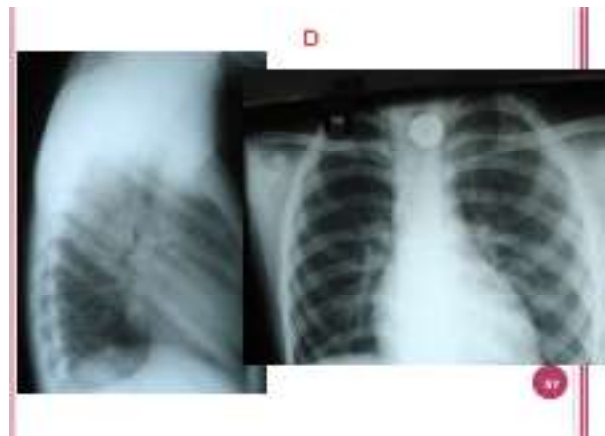


Lesson learnt here: Always take lateral views to avoid surprises

D. With the bad experiences of corrosive necrosis and sharp tops piercing the airway, the team looked at this foreign body suspiciously, despite the cheerful look of the child.

Question: did you notice anything different in this one?

A dot like radiolucency representing the plastic material acting as axis. He did not have any serious symptoms and foreign body was removed successfully and the boy went home uneventfully.



P.S:

*" Authors like coins, grow dear as they grow old: It is the rust we value, not the gold "*

- Alexander Pope (English poet 1688-1744)

*" God was left out of the constitution, but was furnished a front seat on the coins of the countrey "*

- Mark Twain (American humorist, Writer 1835-1910)

