

## Role of FNAC in Diagnosing Tubercular Lymphadenitis: Our Experience

Hamsa S. Shetty\*, Sridhar S.\*\* , Gangadhara K.S.\*\*\*

**Author Affiliation:** \*Junior Resident \*\*Assisntent Professor \*\*\*Professor and HOD, Dept of ENT, McGann Hospital, Shimoga Institute of Medical Sciences, Shivamogga, Karnataka, India.

**Reprint Request:** Hamsa S. Shetty, Junior Resident, Dept of ENT, McGann Hospital, Shimoga Institute of Medical Sciences, Shivamogga, Karnataka-577201, India. E-mail: hamsa.shetty@rediffmail.com

---

### Abstract

*Aim:* To study the accuracy, advantages and limitations of FNAC in diagnosing tubercular lymphadenitis in cases of cervical lymph node swellings. *Materials and Methods:* Retrospective study was conducted over a period of 1 yr which included 72 patients who presented with lymph node swelling in the neck to the ENT outpatient department in our institute. Both males and females from all age groups were included in the study. In all 72 patients FNAC was done. Out of the 72 patients 28 patients agreed to undergo excision biopsy and their histopathological results were compared with the preoperative FNAC results in order to determine the accuracy of FNAC in correctly diagnosing tubercular lymphadenitis in particular. As 28 patients underwent excision biopsy following FNAC, the study group included the above 28 patients only. *Results:* Out of the 28 patients, incidence of males was slightly higher than females and all age group were included, the youngest was a 12 yr old and the oldest was 75 yr old. Out of the 28 patients with lymph node swelling, there were 10 tubercular lymphadenitis, 9 chronic non specific lymphadenitis, 5 metastatic carcinoma and 4 lymphomas proved histologically. The diagnostic accuracy of aspiration cytology was 100% for tubercular lymphadenitis with all the 10 cases proved positive by FNAC. *Conclusion:* FNAC is a simple, quick, economical and least traumatic procedure that can be easily carried out on outpatient basis with high degree of accuracy. As the sensitivity of FNAC in diagnosing tubercular lymphadenitis is extremely high and in our study 100%, this investigation is alone enough to start the patient on medical line of treatment for tuberculosis which helps in reducing the inpatient burden for diagnosing the disease especially in counties like ours where the incidence of tuberculosis is still remains high.

**Keywords:** Fine Needle Aspiration Cytology (FNAC); Accuracy; Excision; Tuberculosis.

---

### Introduction

Tubercular lymphadenitis is a very common cause of superficial cervical lymphadenopathy in our country. FNAC has evolved as one of the most cost effective investigations to diagnose tubercular lymphadenitis. It provides an alternative to excision biopsy for lymph nodes and is an easy procedure for collection of material for cytomorphological and bacteriological examination [1].

The well defined role of FNAC in investigation of lymph node has previously been studied [2,3]. Our study aims at determining the accuracy of FNAC in diagnosing tubercular lymphadenitis in particular

by comparing the cytological findings with post operative histopathological findings. FNAC does not give the same architectural detail as histology but it can provide cells from the entire lesion, as many passes through the lesion can be made while aspirating [4].

### Materials and Methods

A retrospective study of 72 patients who presented with neck swelling to the ENT outpatient department in our institute over a period of 1 yr was done. Detailed clinical history was taken and examination done and all the 72 patients were subjected to FNAC.

FNAC was done using 22-23 gauge, 3-5cm long needle with 10 ml syringe. All 72 patients were advised to undergo excision biopsy so that the cytology report could be compared with the histopathology report and thereby the accuracy of FNAC could be determined.

However out of the 72 patients 58 patients were medically fit to undergo excision biopsy but out of this only 28 patients were willing to undergo the procedure. Therefore the histopathology and FNAC report were compared in these 28 patients.

## Result

Study results compared the preoperative FNAC report with the post-operative histopathology report in 28 patients who underwent excision biopsy. Patients were in the age group between 10 to 80yrs (Table 1). Youngest patient was 12 yrs old who had tubercular lymphadenitis and oldest patient was 75yrs who had chronic non specific lymphadenitis.

### On Clinical Examination

Only 6 out of 28 patients had tenderness over the lymph node swelling. On palpation 16 neck nodes were firm, 5 were hard and 4 rubbery in consistency. Another 3 showed variable consistency.

### Classification of Cytology Reports (Table-3 & Fig 1)

1. In cases where the FNAC features were similar

to HPE report –these were considered Positive.

2. In cases where the cytological features were suspicious of a lesion which was confirmed by histopathology these were considered as Doubtful or Inconclusive.
3. In cases where the cytological features did not correlate with histopathological features these were considered as Negative.

### Diagnostic Accuracy of FNAC in Lymph Node Swellings (Table 4 & Fig 2)

Out of 28 lymph node swellings, there were 10 tubercular lymphadenitis 9 chronic non specific lymphadenitis, 5 metastatic carcinoma and 4 lymphomas proved histologically. The diagnostic accuracy of aspiration cytology was 100% for tubercular lymphadenitis with all the 10 cases proved positive by FNAC.

### False Negative Report

Only in 1 case false negative report was obtained by FNAC. Metastatic squamous cell carcinoma was reported as reactive node. Thus the percentage of false negative report was as low as 3.57%.

### Inadequate Smears:

Smears in which only blood or clear fluid without any cells was seen even after repeated aspiration were considered as inadequate smears. In our study only in 1 case inadequate smear was reported.

**Table 1:**

Age in years	Number of cases with cervical lymph node
11-20	6
21-30	7
31-40	4
41-50	3
51-60	4
61-70	3
71-80	1
Total	28

**Table 2:**

Sex	Number of patients	Percentage
Male	15	53.57%
Female	13	46.43%
Total	28	100%

Males were slightly more in number than females (table 2)

**Table 3:**

Neck swelling	Number of cases who underwent both FNAC and Excisio biopsy	Positive	Doubtful	Negative
Lymph node	28	20 (71.43%)	6 (21.43%)	2(7.14%)

Table 4:

Types of Lymph node swelling	No. of cases Histopathologically proved	No. of case proved positive by FNAC	Percentage
Tubercular lymphadenitis	10	10	100
Chronic non specific lymphadenitis	9	7	77.78
Metastatic carcinoma	5	2	40
Lymphoma	4	1	25
Total	28	20	71.43

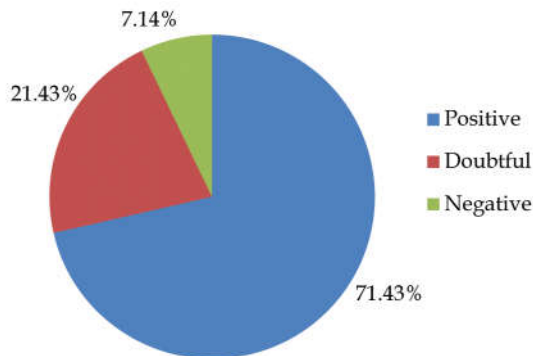


Fig. 1:

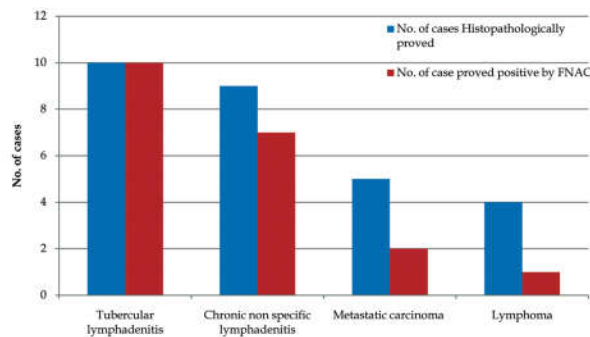


Fig. 2:

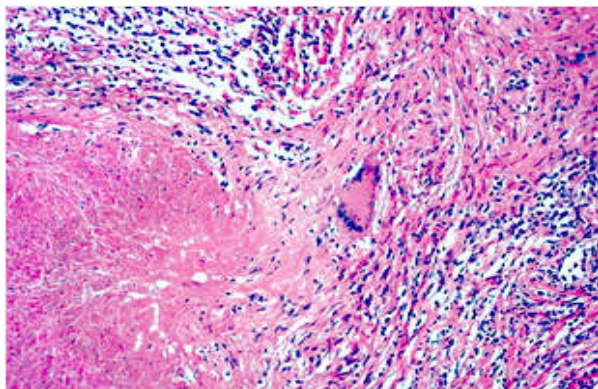


Fig. 3:

#### Inconclusive Smear

FNAC suspicious of a lesion but not definite and the suspicion proved correct after histopathology.

In 6 cases inconclusive smear was reported in our study-1 chronic non specific lymphadenitis, 2 metastatic carcinoma and 3 lymphomas.

## Discussion

Cervical lymphadenopathy is a very common clinical finding and its etiology can be suspected by clinical signs and symptoms. However in suspected cases of tubercular lymphadenopathy a morphological diagnosis is essential to start antitubercular treatment. FNAC thus has contributed in a big way in diagnosing tubercular lymphadenitis as it is a simple to perform, non invasive inexpensive test with high sensitivity in diagnosing tubercular lymphadenitis and can replace excision biopsy, especially in developing country like ours where the burden of disease is still high.

With prevalence as high as 1.5% [5], tuberculosis is still rampant in this part of the world and the tuberculosis involvement of lymph nodes is the most common form of extrapulmonary tuberculosis responsible for 30-40% of cases [6]. FNAC has contributed a great deal to transform cytology from primarily a screening tool to a powerful diagnostic technique [7].

FNAC not only offers tissue diagnosis but serves as a preliminary screening procedure for a number of clinical considerations example lymphoma, leukemia, metastasis, tuberculosis and lymphadenopathy not otherwise specified [8,9,10].

In our study out of 28 cases of lymph node swelling who underwent FNAC and excision biopsy, 10 cases of tubercular lymphadenitis, 9 nonspecific lymphadenitis, 5 metastatic carcinoma and 4 lymphomas were proved histologically. The diagnostic accuracy of aspiration cytology was 100% for tubercular lymphadenitis with all 10 cases proved positive by FNAC thereby none of the tubercular lymphadenitis cases were misdiagnosed or left undiagnosed. Most common cytological pattern was epithelioid clusters with or without langhan's giant cells with necrosis (Figure 3), which is similar to the study by Gupta et al [11]. Only one case out of 28 was reported as false negative by FNAC which was a case of metastatic squamous cell carcinoma and was reported as reactive node.

### 1- Tubercular granuloma

### 2 - Lymphocytes)

The diagnostic accuracy of lymph node swellings of neck varies with different authors. Janes Thamsen et al (1973) reported 90% accuracy in 47 cases, S.K Lau et al (1990) reported 93% accuracy in 68 tubercular lymphadenitis, Yadav S.P.S et al (1991) reported 89.8% accuracy in 50 cases.

In our study, the results are extremely encouraging as diagnostic accuracy of lymphadenitis is 89.47% and all the 10 tubercular lymphadenitis cases were reported positive by needle aspiration making it 100% accurate.

### Conclusion

FNAC is a safe, well accepted procedure by patients, very cost effective and requires minimum instrumentation in comparison to excision biopsy. Diagnostic accuracy is 100% in tuberculous lymphadenitis and therefore in most remote areas FNAC can be used for diagnosing tubercular lymphadenopathy accurately.

### References

1. Ergete W and Bekele A. Acid fast bacilli in aspiration

smears from tuberculous patients. *Ethiop J Health Dev*, 2000; 14(1):99-104.

2. Steel BL, Schwart MR, Ramzy I. Fine needle aspiration biopsy in the diagnosis of lymphadenopathy in 1103 patients. Role, limitations and analysis of diagnostic pitfalls. *Acta Cytol*. 1995; 39(1):76-81.
3. Lioe TFElliott H, Allen DC, Spence RA. The role of fine needle aspiration cytology (FNAC) in the investigation of superficial lymphadenopathy;uses and limitations of the technique. *Cytopathol*. 1998; 10(5):291-7
4. Kirk RM, Ribbons WJ. *Clinical surgery in General*. 4<sup>th</sup> ed. Edinburgh:Elsevier;2004.
5. A K Gupta, M Naya, M Chandra, *Acta Cytol*, 1991; 35:777-782.
6. RR Prasad,R Narasimhan,V Sankaran,A J Veliath, *Diagno Cytol*,1993,15,382-386.
7. Cramer, H. *Fine Needle Aspiration Cytology of the thyroid:an appraisal*.*Cancer Cytopathol*. 2000; 98:325-329.
8. Consensus Statement on childhood tuberculosis, *Indian Paediatrics*, 2010; 47:41-55.
9. A M Amosu,A M Degun,A M Thomas,A O Babalola, *Archives of applied science Research*, 2011; 3:253-265.
10. A Monadi,*Annals of biological Research*, 2012; 3: 3137-3140.
11. Gupta AK,Nayar M,Chandra M.Critical appraisal of fine needle aspiration cytology in tuberculous lymphadenitis.*Acta Cytol*, 1992 May-Jun; 36(3): 391-4.