

Role of Autologous Platelet Rich Plasma (APRP) in Wound Bed Preparation (WBP) of Diabetic Foot Ulcer (DFU)

Chittoria R.K.*, Pandey S.**, Mohapatra D.P.***, Friji M.T.***, Dinesh K.S.***

*Head, **Senior Resident, ***Associate Professor, Department of Plastic Surgery, Jawaharlal Institute of Postgraduate Medical Education and Research (JIPMER) Pondicherry India-605006.

Abstract

Diabetic foot is one of the common conditions faced by surgeons. A multidisciplinary team approach is mandatory for successful treatment of the condition. Its complexity is mainly due to involvement of multiple organs and systems. Hence the condition is often found to be difficult to manage. Various modalities have been evolved time to time for treatment of such condition. General concept is that appropriate and timely healing of wound can prevent various wound related complications like gangrene, auto amputations, septicemia, multiorgan failure, disfigurement, deformities etc. Adjuvant therapy may play an important role here as it is associated with multiple systemic disorders and often the patient is not fit for major surgery. Adjuvant therapy not only increases the wound healing but also can reduce the requirement of graft/ Flap by reducing the size of the defect. Through this article we present use of Autologous Platelet Rich Plasma (APRP) therapy as an effective tool to enhance healing in wound bed preparation of diabetic foot.

Keywords: Diabetic Foot; Wound Healing; APRP.

Introduction

Incidence and prevalence of diabetes is found to be increasing due to changing life and increase in sedentary life style. Almost 25% of patients diabetes are affected with foot ulceration during their lifetime¹.

World Health Organization (WHO) reports show that 32 million people had diabetes in the year 2000 [2,3]. According to estimation of International Diabetes Federation (IDF) total number of diabetic subjects to be around 40.9 million in India and this is further set to rise to 69.9 million by the year 20253 (Figure 1).

Owing to complex nature of the disease and involvement of multiple systems, a well organized and multidisciplinary approach is necessary for its management [4,5]. Diabetes is considered as the most common cause of Charcot neuro-arthropathy in Western countries, a condition that should be

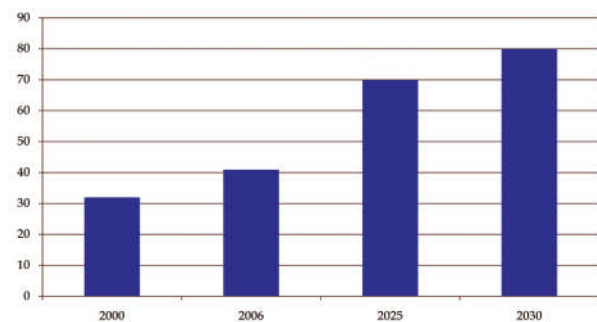


Fig. 1: Estimated number of diabetics in India (in millions)

generally preventable [6].

Burden of Diabetes Related Complications

Diabetes and its related complications cause significant morbidity and mortality, and can be both micro and macro vascular macro vascular [7]. According to Chennai Urban Population Study (CUPS) and CURES the prevalence of coronary artery disease is higher in diabetics as compared to non diabetics (21.4 per cent and 9.1 per cent respectively) [8]. Increased thickness of carotid intima and medial

Corresponding Author: Ravi Kumar Chittoria, Head, Department of Plastic Surgery, JIPMER, Pondicherry, India.
E-mail: drchittoria@yahoo.com

thickness as well as increase in the number of components of metabolic syndrome causes serious complications in diabetes [9]. Similarly the prevalence of peripheral vascular disease (PVD) is also high in diabetics as compared to non diabetics (6.3 per cent

and 2.7 per cent respectively) [10], and these figures are lower than the prevalence reported in western populations [11]. Indian Diabetes Risk Score (IDRS) is an effective tool to know the individual at risk for developing diabetes [12] (Figure 2).

Fig. 2:

Parameters	Indian Diabetes Risk Score	Score
Age (years)		
<35		0
35 to 49		20
>50		30
Abdominal obesity		
Waist <80 cm (female) / <90 cm (male)		0
Waist ≥80-89 cm (female) / ≥ 90 -99 cm (male)		10
Waist >90 cm (female) / >100 cm (male)		20
Physical activity		
Vigorous exercise or very active		0
Mild to moderate exercise or moderately active		20
No exercise and sedentary active		30
Family history		
No family history		0
Either parent		10
Both parents		20

- No risk , if score is < 30
- Medium risk , if score is 30 -50.
- > 50 = high risk for type 2 diabetes and cardiovascular diseases.

Etiology of Diabetic Foot

DFU can be classified as Neuropathic, Ischemic, or Neuroischaemic depending on the involvement of nervous system, vascular system or both, respectively [13].

Concept of Adjuvant Therapy

Involvement of multiple systems, complexity of the disease, less awareness towards symptoms of foot at risk and delayed presentation contributes to the severity of the disease and hence management becomes a challenging task. Patients who present late are usually associated with co morbidities and are often unfit for major surgery and requires systematic approach towards patient and wound both. Adjuvant therapy plays an important role in such patients as an adjunct for wound bed preparation (WBP). While the patient is undergoing work up and primary pathology is being normalized, adjuvant therapy improves wound healing, prevents progression or wound complications and makes the wound fit for surgical procedure. Adjuvant therapy should be easy

to implicate so that it can be used by both medical and surgical staff to enhance the healing process by the time patient is being prepared for anesthesia and surgery.

In our institute we used Autologous Platelet Rich Plasma (APRP) as an adjuvant therapy for preparing the wound bed. Through this article we present a series of 12 Patients of diabetic foot, for whom APRP was used for wound bed preparation and all wounds showed satisfactory outcome in a significantly short duration without major complications.

Methodology

This study was conducted in the department of plastic surgery, JIPMER, Pondicherry, India. This is a retrospective study done during the period of March 2013 to June 2013. 12 cases of diabetic foot were analyzed in whom APRP was used as adjunct for management of diabetic foot (Table 1). All patients and wounds were examined systematically; associated co morbidities were detected and managed according to standard protocol. Ulcer was categorized (neuropathic/ ischemic/ neuroischaemic), wound was graded according to Wagner’s grading system Thorough limb examination was performed [14]. Documentation of ulcer was done according to Bates-Jansen wound assessment tool and digital planimetry

software at the time of presentation and was repeated weekly to access the condition of the wound [15] (Figure 3).

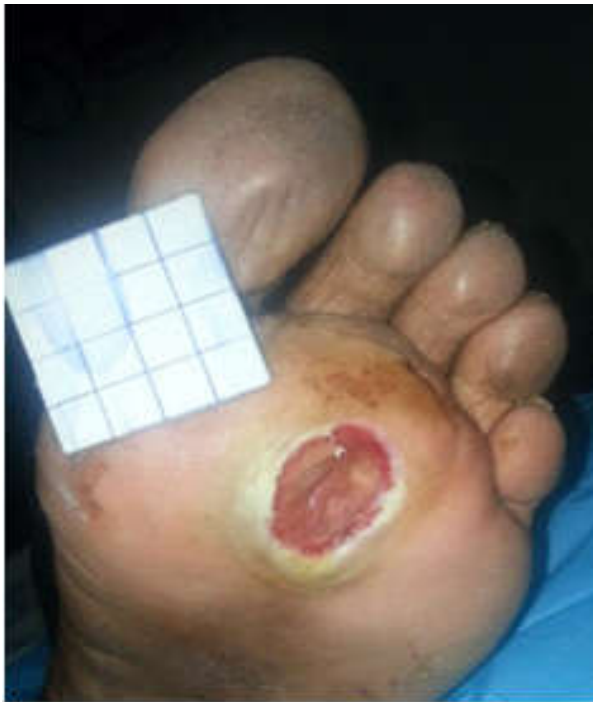

Fig. 3: Digital Planimetry being done

After thorough initial workup and documentation, wound bed preparation was started along with other treatments related to primary pathology. We used TIME concept for systematic and atep wise wound bed preparation (Figure 4) [16].

Wound bed preparation (WBP) by "TIME" concept

- T- Tissue management
- I- Infection and inflammation control
- M- Moisture balance
- E- Epithelial (edge) advancement

Fig. 4: TIME concept of WBP

Surgical and nonsurgical debridement was done for all wounds. Radiofrequency debridement was done for obvious and visible necrotic dead tissue (Figure 5). While in absence of obvious dead tissue the wound's bioburden and microdebris were reduced using Hydrojet technology [17] (Figure 6). To control the infection, systemic antibiotics were used according to the wound culture sensitivity and Nano Crystalline Silver (NCS) was used locally to control wound infection (Figure 7) [18]. Collagen sheet and granules were used as biological dressing to cover the wound (Figure 8) [19]. Autologous Platelet Rich Plasma Therapy (APRP) was used as adjuvant therapy in all wound before application of collagen sheet and granule (Figure 9a to d) [20].




Fig. 5: Radiofrequency Equipment

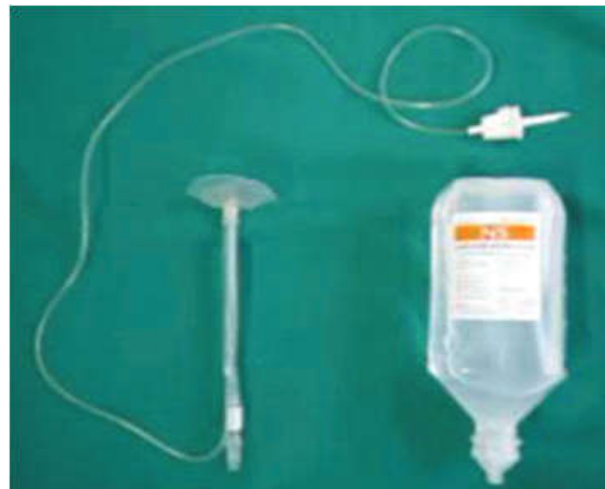

Fig. 6: Hydrojet debridement apparatus Used for debridement

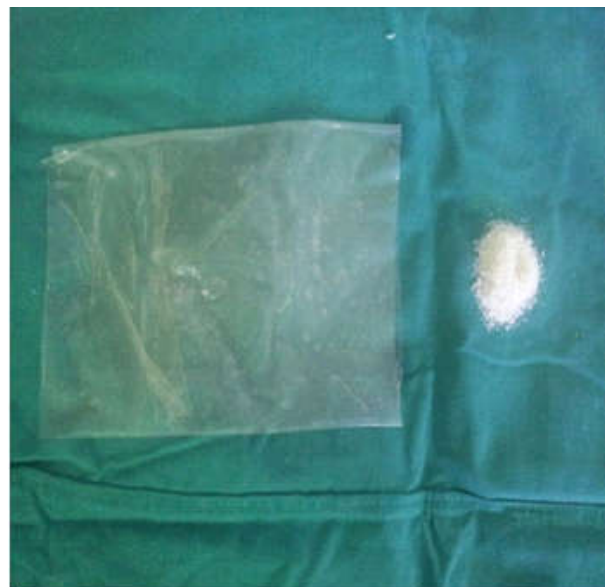

Fig. 7: Collagen sheet and Granules



Fig. 8: Nano Crystalline silver

Preparation of APRP

APRP was prepared using standard and validated technique described by Li W. et al [21,22] as follows:

- Step 1: Informed consent is taken.
- Step 2: Under aseptic precaution, 4.5 ml of whole blood is taken from peripheral vein (Figure 9a).
- Step 3: 0.5 ml of 3.2% Sodium Citrate is added in the 4.5 ml of whole blood (blood: anticoagulant =9:1)
- Step 4: Two plastic tubes, one containing mixture of 4.5 ml whole blood with 0.5 ml of Sodium citrate and other containing 5 ml of normal saline (control) are taken and placed in centrifugation apparatus.
- Step 5: The centrifugation is done at 3000 rpm for 10 minutes (Figure 9b).
- Step 6: After centrifugation 3 portions are seen (Figure 9c). Upper portion containing plasma and platelets, middle portion containing White blood cells (WBCs) with some platelets (Buffy coat) and lower portion containing Red blood cells (RBCs). Middle and lower portions are discarded.
- Step 7: Upper portion is taken in a new tube for re-centrifugation.
- Step 8: Re centrifugation is done at 4000 rpm for 10 minutes.
- Step 9: After re-centrifugation two portions are seen. Upper 2/3rd portion containing platelet poor plasma and lower 1/3rd portion containing platelet rich plasma & erythrocyte with platelet Clump (Figure 9 d).
- Step 10: Upper 2/3rd portion is removed by

syringe & discarded. Remaining Lower 1/3rd portion without clump is used for APRP therapy. Usually from 4.5 ml of blood, 1 to 2 ml of APRP is obtained.

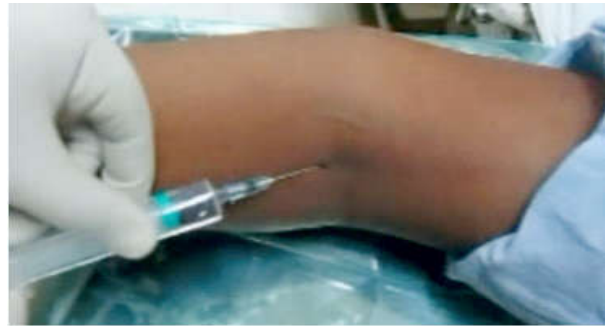

Fig. 9a: Blood being withdrawn for Preparation of APRP



Fig. 9b: Centrifugation tube containing blood is being placed in centrifugation machine

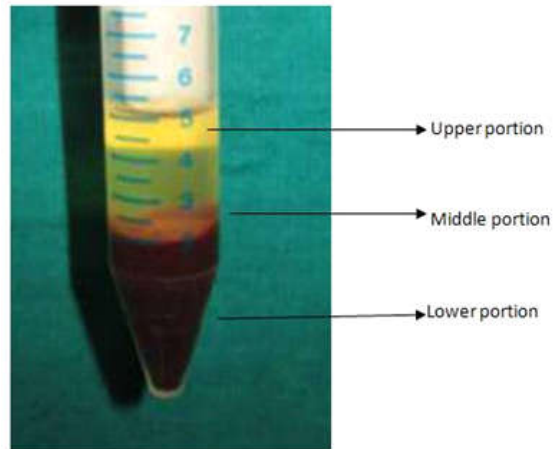


Fig. 9c: Centrifuged tube showing three layers after first rotation.

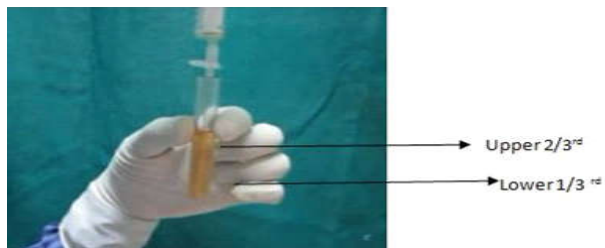


Fig. 9d: After re centrifugation two portions are seen

APRP was injected in the wound margins and wound was covered by biological dressing. The procedure was repeated weekly till wound healed or became fit for reconstruction. Once the wound bed preparation completed various clinical decisions related to repair and reconstruction were taken according to ladder of reconstruction (Figure 10)[23]. Rehabilitative measures were continued post operatively. All the patients were followed up for 6 months for and no complications were noted.

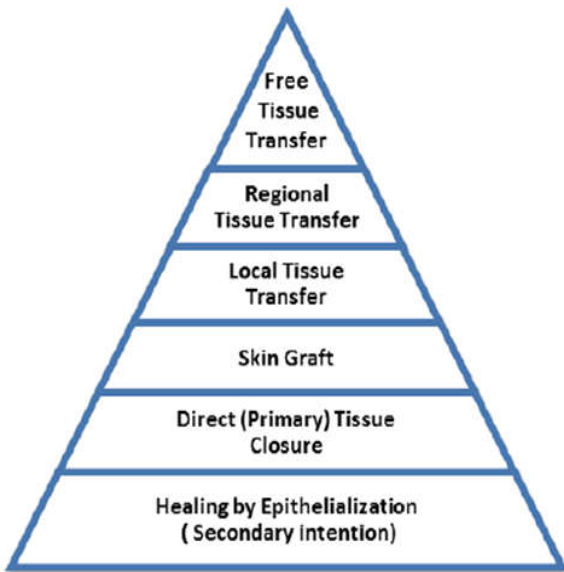


Fig. 10: Ladder of Reconstruction

Result

Twelve patients were included in this study. The mean age was 49.16 years with male to female ratio of 6:1. In 7 patients (58.33%) blood sugar was uncontrolled. The most common co-morbidity was

anemia, in 8 patients (66.66 %), followed by hypertension, in 5 patients (41.66 %) and 3 Patients (25 %) were found to have associated renal diseases. Osteomyelitis was present in 2 patients (16.66%). The most common etiology was spontaneous, in 7 patients (58.33 %) and next most common etiology was trivial trauma, in 4 patients (33.33%). Most common site of wound was distal foot. Mean duration of wound was 11.75 weeks. 9 Patients (75 %) were on injectable insulin and 3 patients (25%) were on oral hypoglycemic drugs. 1 patient (8.33%) presented with associated cellulitic changes. The maximum size of wound was 20 x 8 cm. Mean Bates Jansen Wound Assessment Score was 28. The most common organism grown in tissue culture was pseudomonas, in 4 cultures (33.33%). Methicillin Resistant Staphylococcus Aureus (MRSA) was positive in 1 case (8.33 %). The average duration of systemic antibiotic was 10 days to 3 weeks. The mean duration of wound bed preparation (WBP) was 3.83 weeks.

Autologous Platelet Rich Plasma (APRP) was given in all the 12 cases (100 %). Autologous Lipoaspirate Therapy (ALAT) was used in 2 patients (16.66 %), Autologous Bone Marrow Aspirate Therapy (ABMT) was used in 2 patients (16.66%) and External Tissue Expansion Wound Closure (ETEWC) using rubber bands and hooks were used in 1 patients (8.33%). In 2 patient wound was reconstructed with reverse Sural artery flaps (Figure 11a, b, c) In one patient Wounds was reconstructed with split thickness skin graft (SSG) (Figure 12a, b, c, d) while in 9 patients wound was managed without any surgery by using APRP as an adjunct (Figure13a, b, c). Average duration of wound healing was 10 weeks. No complications were noted in 6 months follow up period (Table 1).

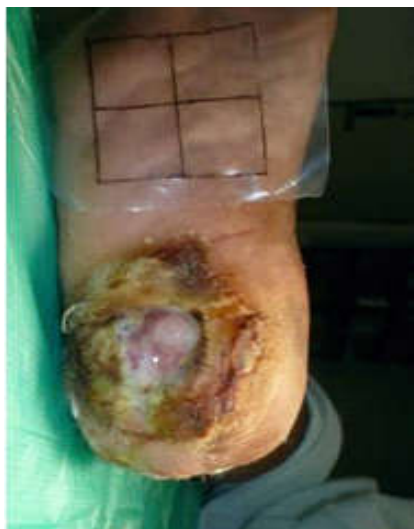

Fig. 11a: Pre operative

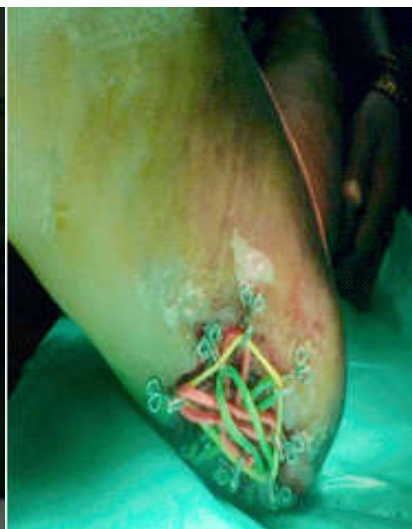

Fig. 11b: ETEWC

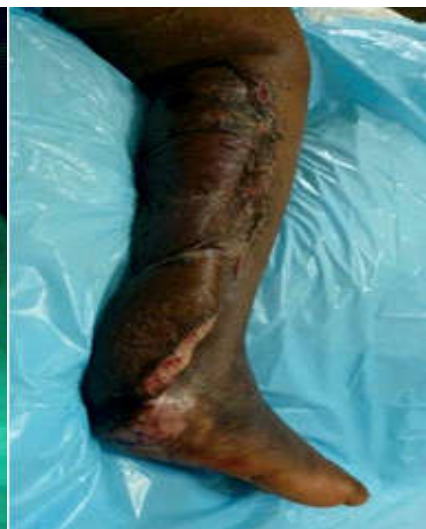

Fig. 11c: reverse Sural artery flap

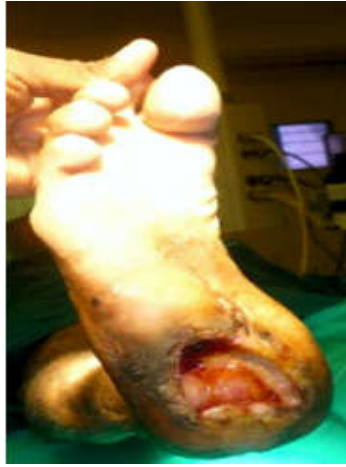

Fig. 12a: Preoperative

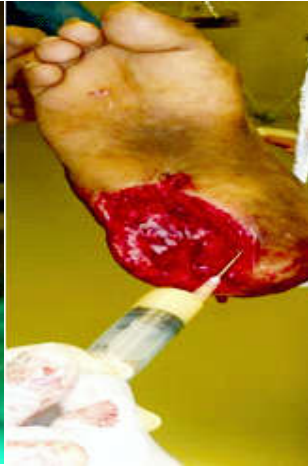

Fig. 12b: APRP

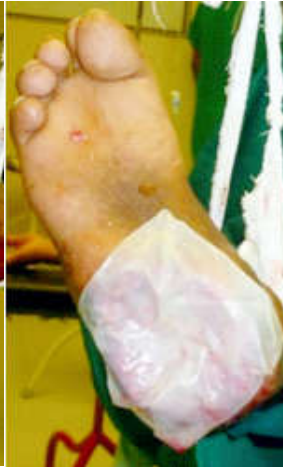

Fig. 12c: Hetrografting

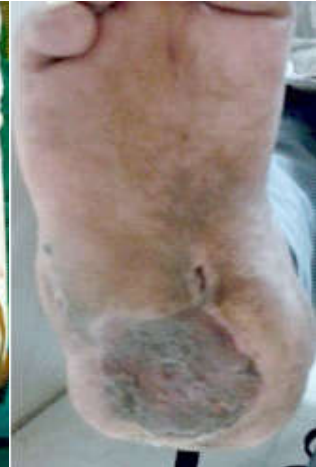

Fig. 12d: SSG

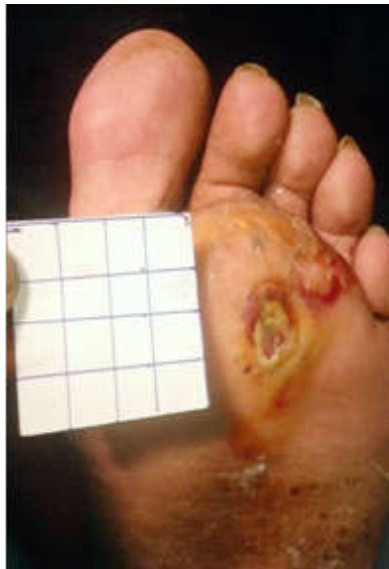

Fig. 13a: Distal foot ulcer

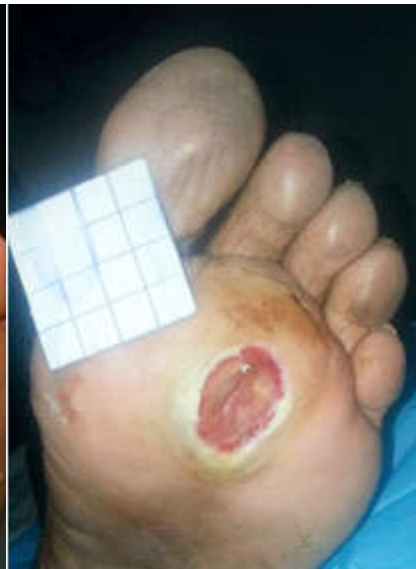

Fig. 13b: After debridement

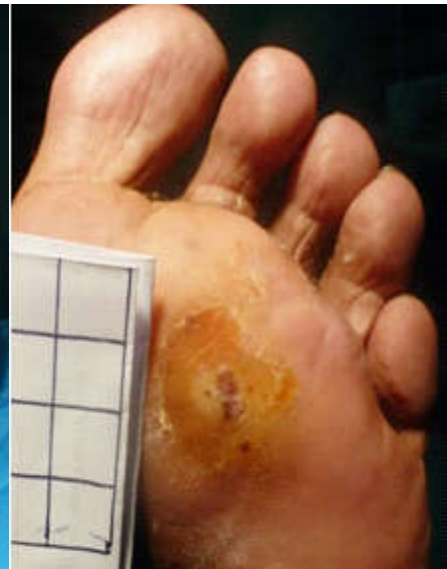

Fig. 13c: Wound healed Completely without surgery

Discussion

Need for Adjuvant Therapy

Wound bed preparation is an important and crucial step of management of any wound. In chronic and non healing wounds which affect multiple systems, normal process of wound healing is failed and wound either requires cover or various internal and external stimulus to heal faster. If patient, wound or both are not fit for surgery, while making the patient and wound fit some adjuvant therapy is needed for wound bed preparation. Adjuvant therapy not only enhances wound healing but also prevent progression of complications and provide suitable wound bed for reconstruction and rehabilitation. Platelet rich plasma (PRP) is blood plasma which contains platelets in higher concentrations as

compared with normal plasma. PRP is also enriched with several growth factors and cytokines that can stimulate wound healing.

The growth factors and other cytokines present in PRP include.

Platelet derived growth factors (PDGF)

- Fibroblast growth factor
- Insulin-like growth factor 1
- Insulin-like growth factor 2
- Transforming growth factor beta (TGF β)
- Epidermal growth factor
- Vascular endothelial growth factor
- Keratinocyte growth factor
- Interleukin 8

Table 1: Case Summary

S. No	Age/Gender	Site	Duration	BJ Store	Wound Measurement	Organism Grown	MRSA	Comorbidity	Osteomyelitis	WBP	Duration of Antibiotics	Duration of NPWT	APRP	ALAT	ABM AT
1	40/M	Distal third of foot	8 weeks	30	6×4cm	E.coli, staphylococcus aureus		Anemia, HTN	no	5 weeks	5 weeks	5 weeks	Yes	No	No
2	35/M	Distal third of foot	6 weeks	36	4.5×7 cm	Sterile		nil	no	4 weeks	3 weeks	4 weeks	Yes	Yes	No
3	45/M	Distal third of foot	12 weeks	24	3×3 cm	Pseudomonas		Anemia	no	5 weeks	4 weeks	5 weeks	Yes	Yes	Yes
4	45/F	heel	16 week	28	2.5×5 cm	sterile		Anemia	no	3 weeks	3 weeks	3 weeks	Yes	No	No
5	56/M	Distal third of foot	21	26	3.5×3.5 cm	pseudomonas		Anemia, HTN	Yes	4 weeks	12 weeks	4 weeks	Yes	No	No
6	50/M	Proximal and mid third of foot	18 weeks	30	18×8 cm	E.coli		Anemia, Hypoproteinemia	Yes	4 weeks	10 weeks	4 weeks	Yes	Yes	Yes
7	48/F	Distal third of foot	20 weeks	29	5×5 cm	MRSA	MRSA	Anemia, HTN, MRD	Yes	5 weeks	10 weeks	5 weeks	Yes	No	No
8	55/M	Distal third of foot	6 weeks	25	4.5×4 cm	staphylococcus aureus		nil	no	3 weeks	2 weeks	3 weeks	Yes	No	No
9	56/M	Distal third of foot	4 weeks	27	4×4 cm	sterile		HTN, MRD	no	2 weeks	4 weeks	2 weeks	Yes	No	No
10	48/M	Distal third of foot	10 weeks	25	3.5×3.5 cm	pseudomonas		Anemia	No	4 weeks	3 weeks	4 weeks	Yes	No	No
11	60/M	Heel	8 weeks	28	4×4 cm	pseudomonas		Anemia, HTN, MRD	No	3 weeks	4 weeks	3 weeks	Yes	No	No
12	52/M	Heel	12 weeks	28	4.5×5 cm	E.coli		nil	No	4 weeks	3 weeks	4 weeks	Yes	No	No

APRP is being in many clinical conditions like nerve injury, androgenic alopecia, osteoarthritis, bone surgeries, oral surgeries, sports injuries etc [24-27].

Through this article we highlight the use of APRP in diabetic foot management, which contains high burden and is associated with high morbidity and mortality.

APRP Versus other Adjuvants

Other adjuvants which can be used for wound bed preparation are lipoaspirate therapy [28], bone marrow aspirate therapy [29], external tissue expansion [30] etc. APRP may be considered as superior to other adjuvant. We found following advantages of APRP

1. Relatively simple technique.
2. Less time consuming,
3. Non invasive
4. No need for anesthesia
5. No associated complications
6. Useful for all wound care providers (doctors,

nurses, general practitioners).

All the patients had successful wound healing without complications in follow up of 6 months. This study has limitations of small sample size, no comparative data and no statistical analysis done. A large randomized controlled study is required to give more significant result for application of APRP in diabetic foot management.

Conclusion

APRP is a simple, easy and effective technique to enhance wound healing and to prevent serious complications related to delayed healing.

Conflicts of Interest

None

Source of Funding

None

Disclosures

None

References

1. Singh N, Armstrong DG, Lipsky BA. Preventing foot ulcer in patients with diabetes. *JAMA* 2005; 293:217-228.
2. Wild S, Roglic G, Green A, Sicree R, King H. Global prevalence of diabetes: Estimates for the year 2000 and projections for 2030. *Diabetes Care* 2004; 27 : 1047-53.
3. Sicree R, Shaw J, Zimmet P. Diabetes and impaired glucose tolerance. In: Gan D, editor. *Diabetes Atlas*. International Diabetes Federation. 3rd ed. Belgium: International Diabetes Federation; 2006; p. 15-103.
4. Assal JP, et al. Patient education in diabetes. In: *Recent Trends in Diabetic Research*, Stockholm: Almqvist and Wiksel International 1982; 276-89.
5. Thomson FJ, et al. A team approach to diabetic foot care: the Manchester experience. *Foot* 1991; 1:75-82
6. Boulton AJM. The diabetic foot: from art to science: the 18th Camillo Golgi lecture. *Diabetologia* 2004; 47:1343-1353.
7. Zargar AH, Wani AI, Masoodi SR, Laway BA, Bashir MI. Mortality in diabetes mellitus - data from a developing region of the world. *Diabetes Res Clin Pract* 1999; 43: 67-74.
8. Mohan V, Deepa R, Rani SS, Premalatha G; Chennai Urban Population Study (CUPS No.5). Prevalence of coronary artery disease and its relationship to lipids in a selected population in South India: The Chennai Urban Population Study (CUPS No. 5). *J Am Coll Cardiol* 2001; 38: 682-
9. Mohan V, Gokulakrishnan K, Sandeep S, Srivastava BK, Ravikumar R, Deepa R. Intimal media thickness, glucose intolerance and metabolic syndrome in Asian Indians- the Chennai Urban Rural Epidemiology Study (CURES -22). *Diabet Med* 2006; 23 : 845-50.
10. Premalatha G, Shanthirani S, Deepa R, Markovitz J, Mohan V. Prevalence and risk factors of peripheral vascular disease in a selected South Indian population: the Chennai Urban Population Study. *Diabetes Care* 2000; 23: 1295-300.
11. Melton LJ, Macken KM, Palumbo PJ, Elveback LR. Incidence and prevalence of clinical peripheral vascular disease in a population-based cohort of diabetic patients. *Diabetes Care* 1980; 3: 650-4.
12. Mohan V, Deepa R, Deepa M, Somannavar S, Datta M. A simplified Indian Diabetes Risk Score for screening for undiagnosed diabetic subjects. *J Assoc Physicians India* 2005; 53: 759-63.
13. International Working Group on the Diabetic Foot. International consensus on the diabetic foot and practical guidelines on the management and the prevention of the diabetic foot. Amsterdam, the Netherlands, 2011.
14. Wagner FW Jr. The dysvascular foot: a system for diagnosis and treatment. *Foot Ankle* 1981; 2:64-122.
15. Bates-Jensen B M. The Pressure Sore Status Tool a few thousand assessments later. *Advances in Wound Care* 1997; 10 (5): 65-73.
16. Chittoria RK, kumar P, Bajaj SP, Singh AK, Gupta DK. General clinical guidelines for wound management: redefining acronym SWCR. *Journal of SWCR* 2014; 7(1): 2-7.
17. Luedtke-Hoffmann KA, Schafer DS. Pulsed lavage in wound cleansing; *Phys Ther* 2000; 80(3): 292-300.
18. Sibbald et al. Screening evaluation of an ionized nanocrystalline silver dressing in chronic wound care. *Ostomy Wound Management* 2001; 47: 38-43.
19. Kumar P. *Skin Substitutes*. In: *Fundamentals of Burns Management*. 2nd edition, Paras Medical Publisher, New Delhi, India 2009; 165-168.
20. Diogo F et al. Protocol for Obtaining Platelet-Rich Plasma (PRP), Platelet-Poor Plasma (PPP), and Thrombin for Autologous Use. *Aesthetic Plastic Surgery* 2012; 36(5): 1254-1259.
21. Franco D, Franco T. Protocol for obtaining PRP for autologous use. *Aesthetic Plast Surg* 2012; 36: 1254-9.
22. Li W, Enomoto M, Ukegawa M et al. Subcutaneous Injections of Platelet-Rich Plasma. *Plast Reconstr Surg* 2012; 129: 858-6.
23. Thorne CH: *Techniques and principles in plastic surgery*. In: *Grabb and Smith's Plastic surgery*. 7th edition. Edited by Thorne CH. New York: Lippincott Williams and Wilkins; 2014; 1-12.
24. Andia I, Sanchez M, Maffulli N. "joint pathology and platelet-rich plasma therapies". *Expert Opinion in Biological Therapies* 2012; 12(1): 7-22.
25. Khatu, Swapna S; More, Yuvraj E; Gokhale, Neeta R; Chavhan, Dipali C; Bendsure, Nitin. "Platelet-Rich Plasma in Androgenic Alopecia: Myth or an Effective Tool". *Journal of Cutaneous and Aesthetic Surgery* 2014; 7(2): 107-110.
26. Esposito M. "Effectiveness of sinus lift procedures for dental implant rehabilitation: a Cochrane systematic review.". *Eur J Oral Implantol*. 2010 Spring; 3(1): 7-26.
27. Mishra A, Woodall J, Vieira A. "Treatment of tendon and muscle using platelet-rich plasma". *Clinics in Sports Medicine* 2009; 28(1): 113-25.
28. Rigotti G et al. Clinical treatment of radiotherapy tissue damage by lipoaspirate transplant: a healing process mediated by adipose-derived adult stem cells. *Plast Reconstr Surg* 2007; 119(5):1409-22.
29. Evangelos V et al. Treatment of chronic wounds with bone marrow- derived cells. *Arch Dermatol* 2003; 139: 510-516.
30. Vijayaraghavan N, Chittoria RK, Mohapatra DP, Friji MT, Dinesh KS, Arjun A. External tissue expansion for difficult wounds using a simple cost effective technique. *Journal of Cutaneous and Aesthetic Surgery* 2015; 8(1): 50-53.