

Breast Tuberculosis Mimicking as Carcinoma Breast in Rural India: Case Series with Literature Review

Md. Tabrez Aziz*, Md. Omar Tabrez**

*Consultant, **Junior Resident, Department of Surgery, Rahmania Medical Centre, Motihari, Bihar, India.

Abstract

Introduction: Breast Tuberculosis (TB) is a rare form of tuberculosis. Incidence of disease is less than 0.1% of all breast lesions in western countries and 4% in TB endemic countries. Breast tuberculosis is one of the extra pulmonary manifestations of tuberculosis.

Case Presentations: In this we present a paper series of 4 cases of breast TB confirmed either pathologically or mycobacteriologically or both. These patient were kept on standard Anti-Tuberculosis Treatment for period of 6 months and all the patients showed a drastic positive response. In all the 4 cases lumps size has decreased along with relief of other symptoms.

Discussion: High risk population is identified, primary and secondary disease is described. Clinical presentation are analysed. Evaluation of diagnostic workup and limitations are reported. *Conclusion:* Mycobacterium should be kept in mind for differential diagnosis in patients who have no response to standard antibiotic therapy with chronic breast or soft tissue infections including recurrent breast abscess. The main striking symptoms of breast tuberculosis are painful breast mass, discharge through the fistula and prolonged symptom duration.

Keywords: Breast Lump; Benign; Tuberculosis; Mammary Tuberculosis; Extra Pulmonary TB.

Introduction

Tuberculosis (TB) has traditionally been regarded

as a pulmonary disorder. However, nearly 17.9% of TB cases have only extra pulmonary manifestations [2]. Breast and skin are considered to be rare sites of extra pulmonary mycobacterial infection, comprising 0.1% to 0.5% of all TB cases, respectively [2]. Tuberculous mastitis is an uncommon lesion [1] even in countries where the incidence of pulmonary and extra pulmonary TB is still very high [3]. The clinician may confuse TB of the breast with either breast carcinoma or abscess [4-6]. Although the usual form of the disease is unilateral, it occasionally presents bilaterally [7].

We summarize here 4 case series of tuberculous mastitis presenting to the Department of Surgery over a period 6months period at Rahmania Medical Centre, Motihari.

Material and Methods

Type of Study

Prospective study.

Centre of Study

Department of Surgery, Rahmania Medical Centre, Motihari.

Inclusion Criteria

Patients with complaints of lump in the breast.

Female patient of age group of 25-50.

Both Out and Inpatient (OPD and IPD).

Corresponding Author: Md. Omar Tabrez, Department of Surgery, Rahmania Medical Centre, Motihari, Bihar-845401.
E-mail: tabrezomar@gmail.com

Exclusion Criteria

Non palpable breast lump disease.

Duration of study: 6 months

Cases Presentation

Case 1

A 45 years old female came with complaint of painless lump in left breast since 6 months. Lump was earlier small in size but has gradually progressed to present size. She also complains of painful ulcer over lower part of left breast along with two discharging sinus over it since 15 days. There was history of pus discharge from nipple with nipple buried. There was no any other significant history.

On physical examination single lump was palpable over upper outer, lower inner and lowerOuter quadrants of left breast which was oval in shape, smooth surface, firm in consistency with margins well defined. Lump was fixed to skin but not

to underlying structure. There was single ulcer with regular margins, sloping edge and discharge over floor, with red healthy granulation base.

There were two discharging sinuses present one over upper outer quadrant and other at lower outer quadrant with pus discharge from it. Nipple was depressed with pus discharging from it.

Two mobile firm apical groups of axillary lymph nodes were palpable. Her routine investigation were normal except raised WBC and ESR. Ultrasound of left breast was suggested left breast abscess with enlarged axillary lymphadenopathy. FNAC from left breast suggested Granulomatous Mastitis.

Although we found no laboratory evidence. The patient's purified protein derivative (PPD)/Monteux skin test was 16 mm in diameter for TB mastitis. ON that basis patient was put on standard anti-TB regimen of isoniazid, rifampicin, pyrazinamide and ethambutol. In the subsequent 6-month period no other sinus tracts appeared and the breast mass showed an apparent remission on multiple sonography.

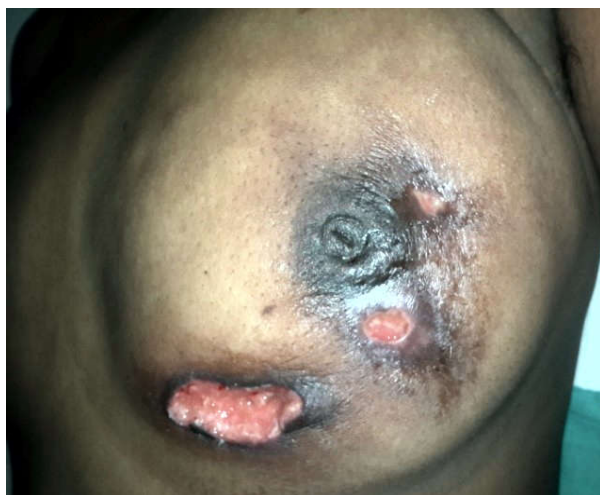
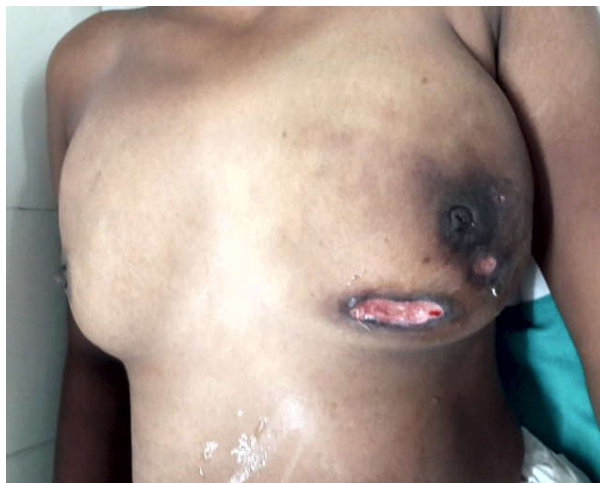
Fig. 1, 2: Showing the diseased breast with ulcer and sinuses

Case 2

A 40-year-old woman presented with pain and lump in the right breast since 4 months. There was an ulcer present over the left breast (Figure 3). She was a known case of Tuberculosis 20 years back and had received a complete 6-month period of anti-TB treatment. The lump progressed rapidly in few days and no associated constitutional symptoms were found.

After ultrasound examination, a biopsy was taken with the suspicion of breast carcinoma. The result was reported as granulomatous mastitis and after ruling out other diagnoses. A course of 6-month anti-




Fig. 3: Showing fullness of left breast with ulcer.

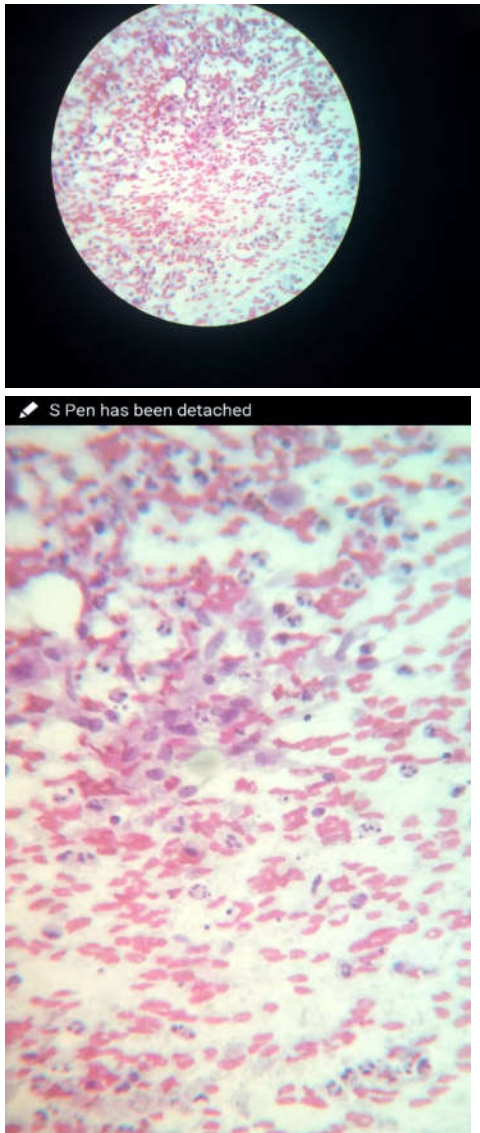

Fig. 4 and 5: Smear stained with PAP stain shows epithelioid cells in the vicinity of acute inflammatory exudate showing tubercular suppuration

TB therapy was started with a standard regimen and showed an excellent response with no mass or abscess reported on ultrasound examination after the course of treatment.

Case 3

A 35-year-old female came to our opd with a complaint of breast pain and lump in of the right breast since 5 months with ulcer over right breast. She had taken different antibiotics but there was no relief.

On physical examination, painful firm to hard mass was palpated in the upper outer quadrant with hyperpigmentation of skin and ulcer in the same quadrant along with a sinus. There was an enlarged

lymph node in right axilla (Figure 6).

The Montoux skin test was negative. Ultrasound suggested an abscess with right axillary lymphadenopathy. Sputum smears were negative; however, FNAC from lump suggested right breast granulomatous suppurative lesion (TB).

A provisional diagnosis of TB was made and a standard anti-TB drug regimen of isoniazid,

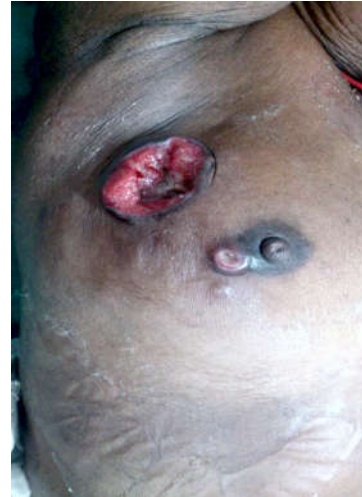

Fig. 6: Right breast showing fullness with ulcer and sinus.

rifampin, pyrazinamide and ethambutol was started on trial.

After beginning of anti-TB medication, the breast ulcer and pain decreased significantly after 2 months.

Case 4

A 49-year-old woman presented with pain and a lump in the right breast since 5 month (Figure 7 and 8). An ultrasound based diagnosis was made and she underwent antibiotic therapy. Due to recurrence, repeated courses of antibiotic therapy were given. A sinus tract appeared in the right breast, superior to the nipple with suppurative secretions Bacteriologic studies at different periods from sinus tract gave negative results.

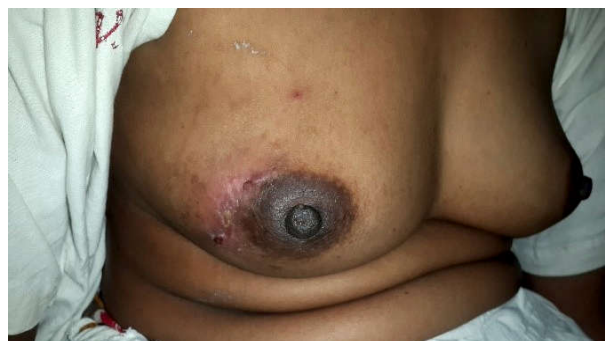

Fig. 7 and 8: right breast along with hypopigmentation and sinus tract seen

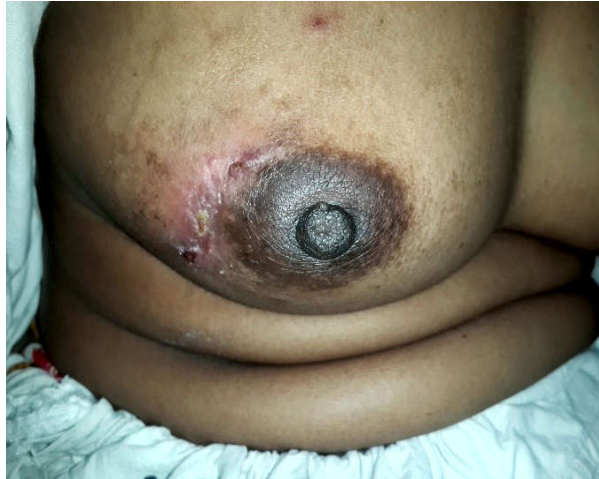


Fig. 8: right breast along with hypopigmentation and sinus tract seen

The PPD/ Montoux skin test was also negative. FNAC from lump suggested left breast granulomatous suppurative lesion suggested of Tuberculosis.

Anti-TB drugs were started and patient showed significantly decrease in mass and pain.

Discussion

Granulomatous mastitis is a descriptive and non-specific term which encompasses many specific lesions such as TB, fungal infections, sarcoidosis and granulomatous reactions in carcinoma [8]. Several diagnoses must be ruled out to establish TB mastitis.

Idiopathic granulomatous mastitis was first described in 1972 [9], for which TB mastitis should always be considered as a differential diagnosis in women with a positive history of exposure to TB patients [10]. This kind of exposure occurs very frequently in endemic countries. A similar granulomatous reaction has also been described in actinomycosis of the breast which can be ruled out by culture of the patient's discharge obtained by FNA in our patients [11]. The best description of TB mastitis is by Shinde et al in India [12]. They showed that a lump in the breast with or without ulceration was the commonest presentation in TB of the breast, the other less common forms being diffuse nodularity and multiple sinuses. Concomitant axillary lymph nodes were found in one-third of the patients. Our second case had similar symptoms. This suggests that a young, multiparous, lactating woman with a similar lesion should always raise the suspicion of TB mastitis, although pre-therapeutic pathologic confirmation of benign conditions is mandatory.

Similar results were reported by Al-Marri et al. from 13 multiparous women with TB of the breast from

Qatar [13]. All of them presented with a lump, 2 had nipple discharge and 1 had a palpable axillary node on the same side. In that study all diagnoses were confirmed histologically.

In both these previous studies the type of breast lesion was similar to what we found in our cases; in our second case, the breast lesion emerged as an abscess, corresponding to Daali's report [14].

According to different studies, the age of patients with breast TB ranges between 20 to 50 years, which corresponds to the age of our patients. However, many other investigators have also reported breast TB in post-menopausal ages [4,6, 15-17].

With regard to pathogenesis, the route of entry of mycobacterial TB to the breast varies.

Spreading of infection from other TB foci via haematogenic path during primary infection is a common route [18]. TB mastitis should also be considered in immunodeficiency states in which pathogenesis is also via the haematogenic route [19,20]. There is also much controversy about the diagnostic criteria for TB mastitis and different surgical biopsies and FNA have been recommended [13]. However, in several studies it has been shown that the overall rate of positivity of AFB in nipple discharge, FNA and tissue samples was 12.0%-22.7% [12,16,21]. Although we obtained samples for smear and direct visualization from breast discharge samples and FNA for all our patients, only patient 3 was AFB-positive.

The differential diagnoses include duct ectasia, foreign-body giant-cell reaction with fat necrosis, foreign material or an abscess, idiopathic granulomatous mastitis, sarcoidosis, syphilitic gumma and Wegener's granulomatosis [16-22], all of which must be ruled out using proper diagnostic tests.

Various modes of therapy ranging from chemotherapy alone to mastectomy have been suggested for tuberculous mastitis [12]. In a study by Shinde et al., 14% of patients required simple mastectomy due to either lack of response to chemotherapy (10%) or large painful, ulcerative lesions involving the entire breast (4%). Axillary dissection was performed in only 8% of patients with large ulcerated axillary nodes.

Al-Marri recommends that incisional or excisional biopsy together with anti-TB drugs is the most successful treatment [13]. Daali et al. recommend anti-TB chemotherapy for 9 months [14].

The clinical course was favourable at 6 months. They recommend that anti-TB antibiotic therapy might

be accompanied by surgery in case of extension, therefore several authors suggest that anti-TB antibiotic therapy in combination with aspiration or surgical drainage are usually associated with an excellent outcome [4,6,7,23,24]. We recommend at least 9 months of anti-TB therapy and surgery in cases with unsatisfactory treatment results.

Conclusion

Mycobacterium should be kept in mind as differential diagnosis in patients who have no response to standard antibiotic therapy with breast lump. The main striking symptoms of breast tuberculosis are painful or painless breast mass, discharge and prolonged symptom duration. It seems that empirical therapy might be effective when primary evaluations for other causes lead to no definite conclusion. Diagnosis is based on tissue diagnosis and it is less probable that a microbiological diagnosis can be made. Therapy includes anti-TB medication, and surgery when indicated.

References

- Cowie RL, Sharpe JW. Extra-pulmonary tuberculosis: a high frequency in the absence of HIV infection. *International journal of tuberculosis and lung disease*, 1997; 1(2):159-62.
- Thompson KS et al. Breast and cutaneous mycobacteriosis: diagnosis by fine-needle aspiration biopsy. *Diagnostic cytopathology*, 1997; 17(1):45-9.
- Akinola DO, Adejuyigbe O, Odesanmi WO. Primary tuberculosis mastitis in Nigerian woman. *West African journal of medicine*, 1989; 8(3):209-12.
- Gong TQ. [Tuberculosis of the breast.] *Zhonghua jie he he hu xi xi ji bing za zhi*, 1989; 12(6):336-7, 380-1 [in Chinese].
- Banerjee A, Green B, Burke M. Tuberculous and granulomatous mastitis. *Practitioner*, 1989; 233(1464):754, 756-7.
- Blasi A et al. La tubercolosi della mammilla. Presentazione di un caso clinic e revisione della letteratura. [Tuberculosis of the breast: report of a clinical case and review of literature.] *Recenti progressi in medicina*, 1989; 80(5):249-51.
- Bonnet P, Fastrez J. La tubercolosi della mammilla. Presentazione di un caso clinic e revisione della letteratura. La tubercolose mammaire: a propos d'un cas. [Breast tuberculosis: a apropos of case.] *Acta chirurgica belgica*, 1987; 87(5):304-6.
- Tse GM et al. Granulomatous mastitis: a clinicopathological review of 26 cases. *Pathology*, 2004; 36(3):254-7.
- Kessler E, Wolloch Y. Granulomatous mastitis: a lesion clinically simulating carcinoma. *American journal of clinical pathology*, 1972; 58:642-6.
- Gupta D et al. Fine needle aspiration cytology in the diagnosis of tuberculous mastitis. *Acta cytologica*, 1999; 43:191-4.
- Jain BK et al. Primary actinomycosis of the breast: a clinical review and a case report. *Journal of dermatology*, 1994; 21(7):497-500.
- Shinde SK, Chandawarkar RY, Deshmukh SP. Tuberculosis of the breast masquerading as carcinoma: a study of 100 patients. *World journal of surgery*, 1995; 19(3):379-81.
- Al-Marri MR, Almosleh A, Almosimani Y. Primary tuberculosis of the breast in Qatar. Ten year experience and review of literature. *European journal of surgery*, 2000; 166(9):687-90.
- Daali M, Hssaisa R, Had A. La tubercolose primitive du sein. [Primary tuberculosis of the breast.] *La Presse medicale*, 2001; 30(9):431-3.
- Gupta R, Gupta AS, Duggal N. Tubercular mastitis. *International surgery*, 1982; 67(4 Suppl.):422-4.
- Cohen C. Tuberculous mastitis. A review of 34 cases. *South African medical journal*, 1977; 52(1):12-4.
- Wojcik A, Spilarewicz A. [Tuberculosis of the breast.] *Pneumonologia polska*, 1989; 57(5):315-7 [in Polish].
- Talantov VA. [Difficulties in the differential diagnosis of tuberculosis of the breast.] *Vestnik khirurgii imeni I. I. Grekova*, 1979; 123(12):15-8 [in Russian].
- Hartstein M, Leaf HL. Tuberculosis of the breast as a presenting manifestation of AIDS. *Clinical infectious diseases*, 1992; 15(4):692-3.
- Mendes Wda S, Levi M, Levi GC. Breast tuberculosis: case report and literature review. *Revista do Hospital das Clinicas*, 1996; 51:136-7 [in Portuguese].
- Gupta D et al. Fine needle aspiration cytology in the diagnosis of tuberculous mastitis. *Acta cytologica*, 1999; 43(2):191-4.
- Stappaerts I et al. Granulomatous mastitis as presenting sign of Wegener's granulomatosis. *Acta clinica belgica*, 1999; 54(4): 207-10.
- Al Soub H, Chacko K. Tuberculosis mastitis: a rare disease. *British journal of clinical practice*, 1996; 50(1):50-1.
- Ikard RW, Perkins D. Mammary tuberculosis: a rare modern disease. *Southern medical journal*, 1977; 70(2):208-12.