

## Shepherd's Crook Deformity of Mono-ostotic Fibrous Dysplasia Treated with Corrective Osteotomy and 95 Degree Hip Screw

Pradeep Choudhari\*, Hemant Mandovra\*\*

**Author Affiliation:** \*Professor in Department of Orthopaedics & Traumatology, Sri Aurobindo Institute of Medical Sciences (SAIMS), Indore, M.P.India. \*\*Consulting Orthopaedic Surgeon Indore, Madhya Pradesh, India.

**Reprint Request:** Pradeep Choudhari, 7/3/3, Ahilaya Mata Colony, Near Charak Hospital, Rani Sati Gate, Indore-452003.  
E-mail: [pchoudhari@rediffmail.com](mailto:pchoudhari@rediffmail.com)

---

### Abstract

Fibrous dysplasia, a condition in which the skeleton fails to develop normally, is characterized by fibroblastic stroma and immature bone. Bowing of the long bones occurs frequently and stress fractures often result. Shepherd's crook deformity of hip is a characteristic feature of fibrous dysplasia. The goal of its treatment is to obtain normal walking ability and relieve pain due to pathologic fracture secondary to the deformity; however, correction of the deformity is a surgical challenge. We present 2 cases of Shepherd's Crook deformity treated with corrective osteotomy and a 95 degree Hip screw. Both cases showed good bone healing and no recurrent deformity. The gross deformities were corrected, and both patients were pain-free after operation.

**Keywords:** Corrective Osteotomy; 95 Degree Hip Screw; Fibrous Dysplasia; Shepherd's Crook Deformity.

---

### Introduction

Fibrous dysplasia is a benign bone lesion resulting from congenital dysplasia of skeletal tissue. It is characterized by fibro-osseous tissue replacing normal bone tissue. According to its clinical patterns, fibrous dysplasia can be divided into 3 types: monostotic, polyostotic, and Albright's syndrome. Patients with the monostotic type have a single or multiple areas of involvement (which may or may not be confluent) in a single bone. Monostotic fibrous dysplasia accounts for about 70% of all cases of fibrous dysplasia. Patients with the polyostotic type have involvement of multiple bones. Albright's syndrome is a polyostotic type of dysplasia associated with abnormal skin pigmentation and pathologic endocrine dysfunction. When the weight of the body acts through the mechanically weakened bone, deformity gradually develops.

One well recognized deformity in polyostotic fibrous dysplasia is Shepherd's Crook deformity, which causes severe varus in the proximal femur. Untreated Shepherd's Crook deformity results in limb shortening, limping and occasionally chronic fatigue fracture accompanied by disabling pain. However, the treatment of Shepherd's crook deformity is challenging because of the severely deformed and weakened bone.

We present 2 cases of Shepherd's Crook deformity of hip successfully treated with corrective osteotomy and internal fixation with a 95 degree hip screw.

### Case Reports

#### Case 1

A 20-year-old man presented with a varus deformity of left hip and shortening of Left lower limb which was supratrochantric. Plain X ray of

pelvis with both hips revealed typical ground glass appearance of the bone with Shepherd's Crook deformity of proximal femur, and the femoral neck-shaft angle measured 60 degree (Figure 1 and 2).

He had a fall and sustained a pathological fracture below the Shepherd Crook deformity. Patient had pain, swelling and deformity of left upper thigh with shortening of 11 cm in left lower limb.

Lateral closed-wedge osteotomy was performed using an orthopedic table and C arm guidance. The osteotomy was fixed with 10 hole, 95 degree hip screw (Figure 3). No additional bone graft was used.

Postoperatively, non-weight-bearing ambulation was advised for 2 months followed by partial weight bearing for another 2 months. Follow-up radiograph 3 months after the operation revealed satisfactory union at the osteotomy site. The shortening of the limb was corrected from 11 cm preoperatively to 4 cm postoperatively. The femoral neck-shaft angle was corrected from 60 degree preoperatively to 130 degree postoperatively.

The radiographs at 6 months and 14 month follow up after the surgery revealed no recurrence of deformity of the neck-shaft angle and the implant holding well with satisfactory union (Figure 4 and 5).

The patient is free of hip pain, but has mild limping, and has been advised compensatory shoe raise because of his 4-cm limb-length shortening. The range of motion at the affected hip and ipsilateral knee is normal.

#### Case 2

A 17 year old girl presented with pain and deformity left hip. She was walking with a limp on left side. On examination she had a shortening of 8.5cm in the left lower limb. Radiographs revealed a typical Shepherd's Crook deformity of the left proximal femur (Figure 6). The neck-shaft angle of the left femur was 80 degree.

The patient underwent lateral closed wedge osteotomy for correction of the left proximal femur deformity (Figure 7). The osteotomy was fixed with a 9 hole, 95 degree hip screw. No bone grafting was done.

The leg-length discrepancy was corrected from 8.5-cm shortening preoperatively to 1 cm postoperatively and the femoral neck shaft angle was corrected to 120 degree. Postoperatively non-weight-bearing ambulation was advised for 2 months and partial weight bearing for another 2 months. The Patient returned to normal activity without symptoms 6 months after surgery.

At 6 months postoperative follow-up, the femur showed good union and alignment radiographically.

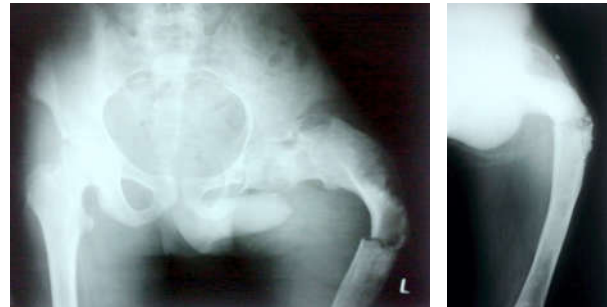


Fig. 1: Preoperative radiographs

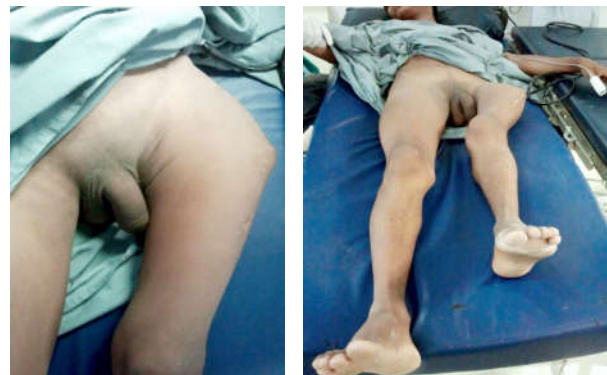

Fig. 2: Preoperative clinical photographs

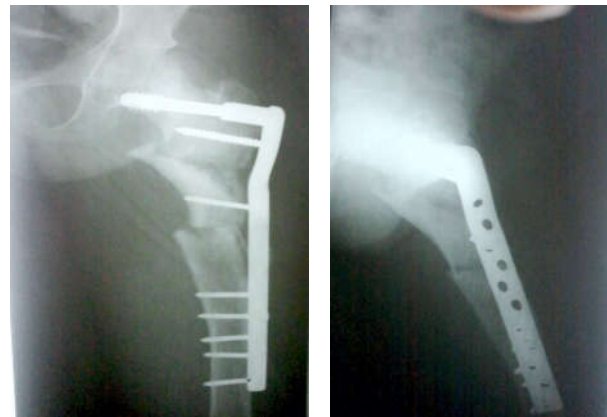

Fig. 3: Post operative radiographs

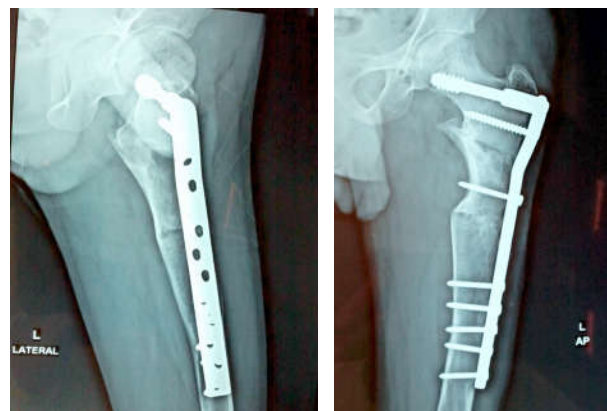


Fig. 4: Post operative radiograph at 6 months follow up

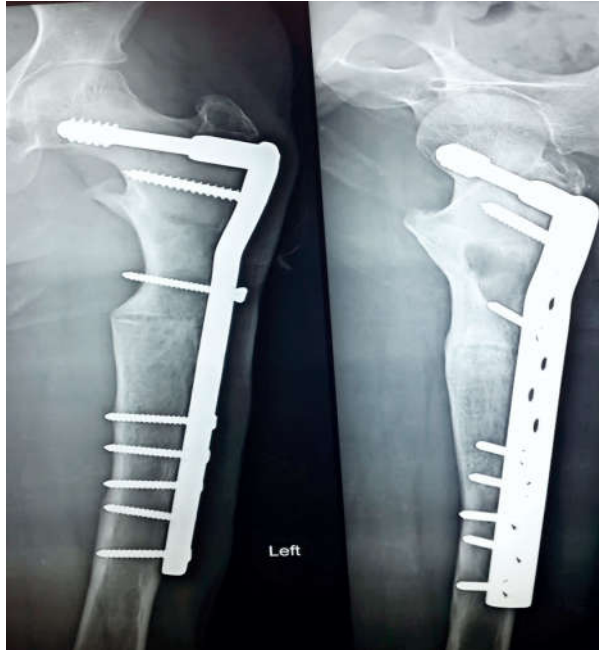

Fig. 5: Post operative radiograph at 14 months follow up

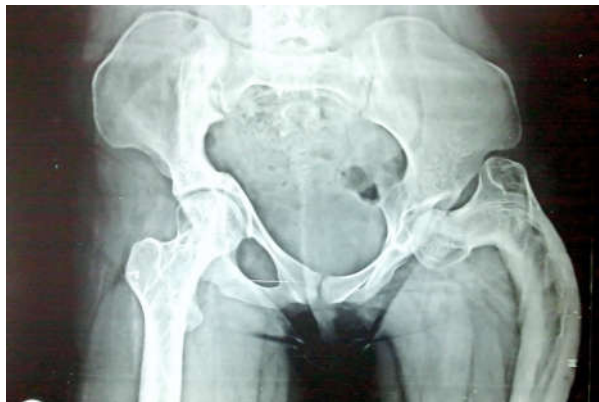

Fig. 6: Preoperative radiograph case 2

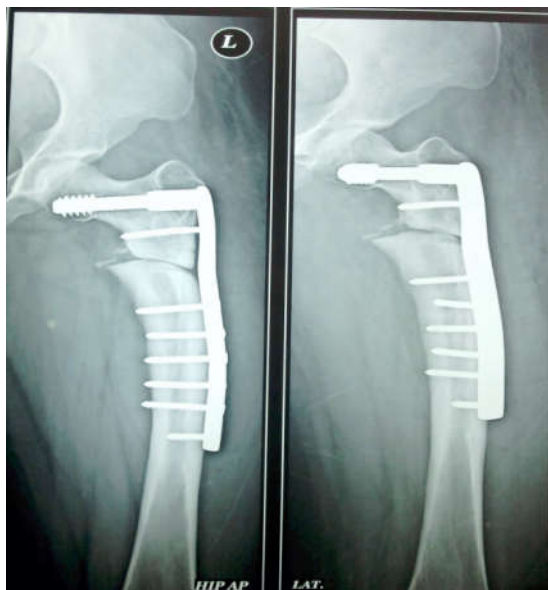

Fig. 7: Post operative radiograph case 2

## Discussion

Fibrous dysplasia is a benign bony lesion that usually becomes quiescent after adolescence [10]. Despite its benign character, however, it may cause problems, because normal bone is replaced with fibrous tissue.

When the weight of the body and the strong gluteal muscles act on the weakened proximal femur, plastic deformity gradually develops and stress fracture may occur. There are various procedures for treating proximal femoral lesions in fibrous dysplasia, including curettage and bone grafting, valgus osteotomy, plating and hip nailing, intramedullary nailing, and cortical bone grafting [8,9]. Russell and Chandler [7] reported 11 cases of fibrous dysplasia treated surgically in 1950. They concluded that the indications for surgery in fibrous dysplasia were continued pain in the region of a localized bone lesion, fracture through a lesion, or severe deformity. Since mechanical stress is the most important cause of deformity after puberty, proper internal fixation can provide a type of mechanical support, although disease progression cannot be altered.

There are various options for treating Shepherd's Crook deformity, but no single type of internal fixation appears to provide a major advantage over the others. Breck [1] reported a case of fibrous dysplasia treated with total femoral plating and hip nailing, without further fracture or subsequent implant failure. Connolly [3] and Freeman et al [4] reported the use of osteotomies with Zickel nail fixation to correct and control deformity. As the femoral head is often spared from the disease, firm purchase of the implant in the femoral head provides sufficient mechanical support and reduces the recurrence rate of the deformity.

In the present report, osteotomy with internal fixation using a 95 degree hip screw had good results. We used a paper template to evaluate the osteotomy level preoperatively. By folding the template to the normal neck-shaft angle, it was possible to estimate the osteotomy level and length of the closed-wedge. It was not difficult to apply the fixation device after the single-level corrective osteotomy had been finished. The side plate should be long enough to provide adequate fixation of the mechanically deficient femur and to prevent the recurrence of deformity and implant failure. In our cases, fixation was achieved with a 10-hole side plate in first case and an 8-hole side plate in the other. An Intramedullary device may be another option, because it can also provide good mechanical support

over the femoral neck. In addition, it possesses a shorter level arm than a dynamic hip screw, and has a lower bending moment on the femoral neck. However, an Intramedullary device is difficult to introduce, and may easily protrude from the canal because of the difficulty in locating a good entrance point and the deformed proximal femur.

As previous studies have shown that fibrous dysplasia possesses normal bone-healing potential [13] we did not make additional autologous bone grafts from the iliac crest or other sites over the osteotomy site. The uneven lateral cortex after the single-level osteotomy was filled with the bone chips from the excised bone wedge. The osteotomy site in both cases healed within 6 months. Dysplastic bone may have the capability to heal at a rate comparable to that of normal bone [14].

From our limited experience, we believe that corrective osteotomy and Internal Fixation with 95 degree Hip screw is a good and effective method for treating severe symptomatic Shepherd's Crook deformity. This procedure can provide full contact with the osteotomy surface and is relatively easy, and the healing capability of dysplastic bone does not seem to be a cause for concern.

## References

1. Breck LW. Treatment of fibrous dysplasia of bone by total femoral plating and hip nailing. *Clin Orthop.* 1972; 82: 82-3.
2. Funk FJ Jr, Wells RE. Hip problems in fibrous dysplasia. *Clin Orthop.* 1973; 90: 77-82.
3. Connolly JF. Shepherd's crook deformity of polyostotic fibrous Dysplasia treated by osteotomy and Zickel nail fixation. *Clin Orthop.* 1977; 23: 22-4.
4. Freeman BH, Bray EW 3rd, Meyer LC. Multiple osteotomies With Zickel nail fixation for polyostotic fibrous dysplasia involving the proximal part of the femur. *J Bone Joint Surg [Am].* 1987; 69: 691-8.
5. Ozaki T, Sugihara M, Nakatsuka Y, Kawai A, Inoue H. Polyostotic fibrous dysplasia: Long terms follow up of 8 Patients. *Int Orthop.* 1996; 20: 227-32.
6. Enneking WF, Gearen PF. Fibrous dysplasia of the femoral Neck: treatment by cortical bone-grafting. *J Bone Joint Surg [Am].* 1986; 68: 1415-22.
7. Russell LW, Chandler FA. Fibrous dysplasia of bone. *J Bone Joint Surg [Am].* 1950; 32: 323-37.
8. Stephenson RB, London MD, Hankin FM, Kaufer H. Fibrous Dysplasia: an analysis of options for treatment. *J Bone Joint Surg [Am].* 1987; 69: 400-9.
9. Guille JT, Kumar SJ, MacEwen GD. Fibrous dysplasia of the Proximal part of the femur: long-term results of curettage and Bone-grafting and mechanical realignment. *J Bone Joint Surg [Am].* 1998; 80: 648-58.
10. Harris WH, Dudley HR Jr, Barry RJ. The natural history of Fibrous dysplasia: an orthopedic, pathological, and Roentgenographic study. *J Bone Joint Surg [Am].* 1962; 44: 207-33.
11. Yamamoto T, Hashimoto Y, Mizuno K. Oblique wedge Osteotomy for femoral diaphyseal deformity in fibrous dysplasia. *Clin Orthop.* 2001; 384: 245-9.
12. Enneking WF. Fibrous lesion originating in bone. In: *Musculoskeletal Tumor Surgery.* New York: Churchill- Livingstone. 1983: 855-67.
13. Campanacci M. Fibrous dysplasia. In: *Bone and Soft Tissue Tumors, 2nd edition.* New York: Springer-Verlag Wien. 1999: 435-61.
14. Wei-Jen Chen, Wei-Ming Chen\*, Shepherd's Crook Deformity of Polyostotic Fibrous Dysplasia Treated with Corrective Osteotomy and Dynamic Hip Screw. *J Chin Med Assoc.* July 2005; 68(7).

