

Comparison of Endothelial Cell Density in Pseudoexfoliation Syndrome and Pseudoexfoliation Glaucoma

Shilpa Umarani¹, Jay Singh B N², Jayshree M P³, Shishir K N⁴, Ramesh C Hulakund⁵, Shilly Varghese⁶

Abstract

Purpose: Evaluation of endothelial cell density (ECD) in patients of pseudoexfoliation (PEX) syndrome with glaucoma (PEXG) and without glaucoma using specular microscopy. **Material and methods:** The study included 142 patients (236 eyes). In this group of patient we identified 166 eyes with PEX syndrome (80 with glaucoma, 86 without glaucoma) and 70 eyes without PEX syndrome. ECD was measured in each eye by specular microscopy. **Results:** ECD in eyes with PEX syndrome without glaucoma (2286 ± 348 cells/mm²) and in eyes with PEXG (2237 ± 353 cells/mm²) was lower than in the control group (2513 ± 265 cells/mm²) ($P < 0.001$). **Conclusion:** This research shows that in eyes with PEX syndrome, both with and without glaucoma, ECD was statistically significantly lower than in the control group.

Keywords: Pseudoexfoliation syndrome; Pseudoexfoliation glaucoma; Endothelial cell density; Specular microscope.

How to cite this article:

Shilpa Umarani, Jay Singh B.N., Jayshree M.P., et al./ Comparison of Endothelial Cell Density in Pseudoexfoliation Syndrome and Pseudoexfoliation Glaucoma./ Ophthalmol Allied Sci. 2021;7(1):15-19.

Introduction

Pseudoexfoliation (PEX) syndrome is an age-related systemic disorder with strong genetic predisposition.¹⁻³ It is characterized by formation and deposition of abnormal extracellular grey white dandruff like material in tissues most commonly in anterior chamber of the eye.⁴ The material is classically found on the corneal endothelium, anterior lens surface, iris, trabecular meshwork, zonules and ciliary body.^{2,5,6} This can lead to many pathological conditions of the eye like corneal endothelial decompensation, secondary open angle glaucoma, zonular weakness resulting

in phacodonesis, lens dislocation, capsule rupture and vitreous release during cataract surgery and poor pupillary dilation.⁷

The corneal endothelium is made up of single layer of hexagonal cells without regeneration ability. Its function is to maintain the hydration of the cornea. The normal density in adults is approximately 2500 cells/mm² and it is reduced by 0.6% per year. When the density is reduced to approximately 800 cells/mm², it can lead corneal decompensation causing corneal edema.⁸

This study was aimed to asses corneal endothelial cell density in patients of PEX syndrome with and without glaucoma using specular microscope.

Material and Methods

Total 236 eyes of 142 patients were examined for PEX syndrome who came to the Department of Ophthalmology, S. N. Medical College & HSK

Author Affiliation: ¹Assistant Professor, ^{2,4,5,6}Junior Resident, ³Professor, S Nijalingappa Medical College & HSK Hospital, Bagalkot, Karnataka 587102, India.

Corresponding Author: Jay Singh B N, Junior Resident, S Nijalingappa Medical College & HSK Hospital, Bagalkot, Karnataka 587102, India.

Email: drjay.alwayswithu14@gmail.com

Hospital, Bagalkot. This prospective study was done during the period of 1.5 years from November 2019 to April 2021. Patients with history of previous ocular surgery, glaucoma without PEX syndrome, history of ocular trauma and corneal pathology were excluded from the present study.

The study was approved by the ethical committee in accordance with ethical standards laid down in 1964 Declaration of Helsinki. Informed consent forms were signed by all the patients included in this study.

Sample size Estimation

Sample size estimation was done using Open EPI Software Version 2.3.1.

At 95% confidence level, and 80% power of the study α (two-tailed) = 0.050 and at 95% confidence level. β = 0.200 and 80% of power of the study Where $Z\alpha$ =standard table value for 95% CI=1.96

$Z1-\beta$ =Standard table value for 80% Power=0.84 Based on previous study,etal, Mean CCT in PEX Group=529.7±30.3

Mean CCT in PEXG Group=508.2±32.6

Sample size is calculated using the formula, $n=2(Z\alpha+Z1-\beta)^2\sigma^2/d^2$

Sample size estimated is 44 which is rounded off to 50 patients in PEX and 50 in PEXG group.

The patients were divided into three groups: group PEX, which included 48 patients of PEX syndrome without glaucoma (86 eyes—47 corneas in 27 men and 39 corneas in 21 women), group PEXG, which included 43 patients with PEXG (80 eyes—42 corneas in 23 men and 38 corneas in 20 women), and group CNT, which included 51 patients without coexisting PEX syndrome (70 eyes- 41 corneas in 29 men and 29 corneas in 22 women).

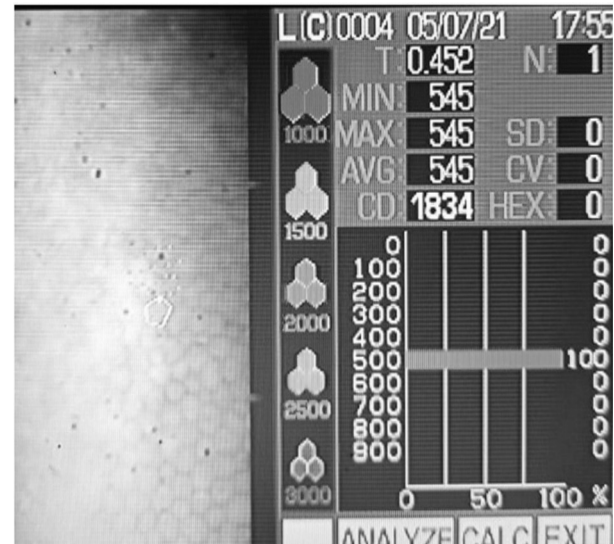
PEX syndrome patients were diagnosed on the basis of sign seen during slit lamp biomicroscope examination. Patients with cup:disc ratio >0.5, intraocular pressure >21mm Hg and visual field defects were included in PEXG group excluding previous diagnosis and treatment of PEXG glaucoma.

All patients underwent complete eye examination which included visual acuity evaluation for distance and near vision using Snellen's chart, IOP measurement using Goldmann appplanation tonometry, anterior segment examination using slit lamp biomicroscope, visual field analysis using Octopus perimetry and fundus examination using

volk 90 D aspheric lens. B-scan was done in the patients with severe media opacity.

ECD was assessed in all patients using specular microscopy Topcon SP-3000 P in automatic mode. For getting accurate measurement of ECD, 60 adjacent cells were selected manually of a 0.5×0.25 mm section of endothelial surface. Three readings were taken in each eye and average ECD value were taken for further calculations.

Fig. 1: Specular photomicrograph from Topcon SP-3000P specular microscope. CD: cell density.



Plan for statistical analysis of the study

Statistical analysis will be done using SPSS software 19.0. Data obtained will be tabulated in the Excel sheet and will be analysed. Quantitative data will be expressed as mean ± standard deviation and nonparametric data will be expressed as median and min-max values. Percentages are used for representing qualitative data. Chi-square test for proportions in qualitative data. Student t test for quantitative data will be used Other appropriate statistical tests will be applied. P<0.05 will be considered statistically significant.

Result

In this study as shown (table 1), PEX group consists of 48 patients out of which 27 were male and 21 were female (figure 2), the mean age was 72.37±6.12. PEXG group consists of 43 patients out of which 23 were male and 20 were female (figure 3) with mean age of 75.64±7.45. CNT group consists of 51 patients out of which 29 were male and 22 were female (figure 4) with mean age of 73.52±6.98.

Table 1: Patients demographics

Groups	Number of patients	Age, Y (Mean ± SD)
PEX	48	M-27 72.37± 6.12
		F-21 73.52 ± 6.98
PEXG	43	M-23 75.64 ± 7.45
		F-20 74.87 ± 8.25
CNT	51	M-29 71.65 ± 6.59
		F-22 76.36 ± 7.38

CNT: control group; PEX: pseudoexfoliation syndrome group; PEXG: pseudoexfoliation glaucoma group; F: female; M: male.

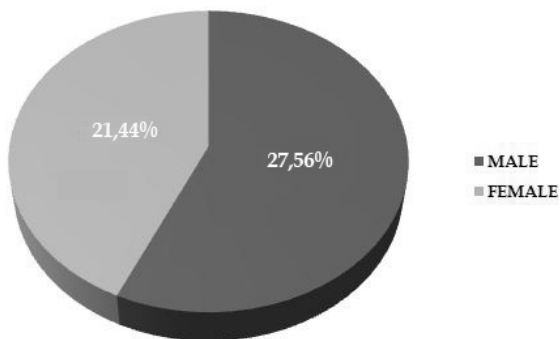


Fig. 2: PEX (pseudoexfoliation group).

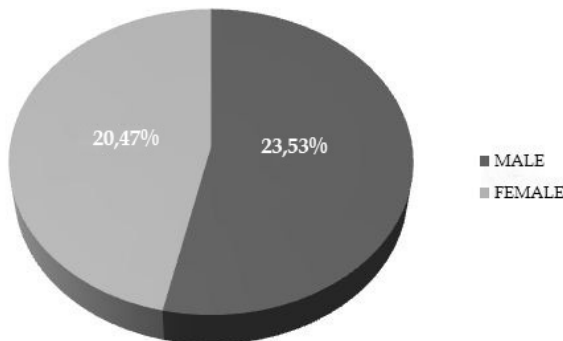


Fig. 3: PEXG (pseudoexfoliation glaucoma group).

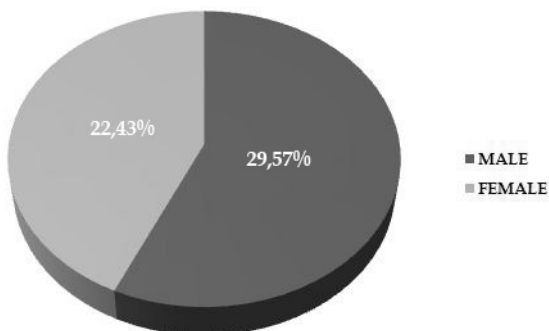


Fig. 4: CNT (control group).

In PEX group (Figure 5), ECD (2286 ± 348 cells/ mm^2) was low as compare to CNT group (2513 ± 265 cells/ mm^2) with statistical significance at $P = 0.0009$. In PEXG group, ECD (2237 ± 353 cells/ mm^2) was low as compare to CNT group with statistical significance at $P = 0.000006$. The difference between group PEX and PEXG was not statistically significant with $P = 0.72$ (table 2).

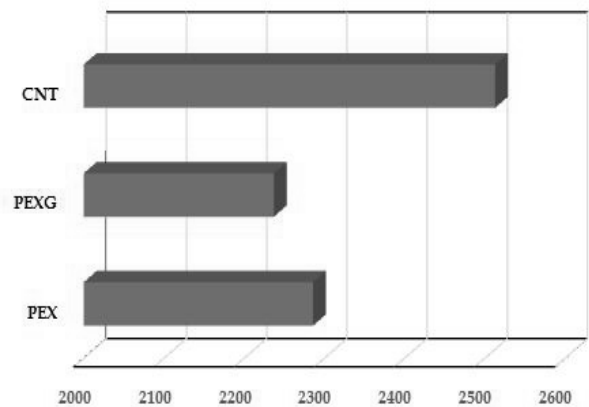


Fig. 5: Evaluation of cell density (ECD) in groups of patients with pseudoexfoliation syndrome (PEX), pseudoexfoliation glaucoma (PEXG) and control group(CNT).

Table 2: Summary of results.

Groups	ECD (cells/ mm^2)	p
PEX versus CNT	2286 ± 348 versus 2513 ± 265	0.0009
PEXG versus CNT	2237 ± 353 versus 2513 ± 265	0.000006
PEX versus PEXG	2286 ± 348 versus 2237 ± 353	0.72

CNT: control group; PEX: pseudoexfoliation syndrome group; PEXG: pseudoexfoliation glaucoma group; ECD: endothelial cell density.

Discussion

Specular microscopy was used in this study to compare ECD in patients with PEX syndrome, with PEXG and in CNT group. Results demonstrated that PEXG group showed the lowest cell density of endothelium (2237 ± 353 cells/ mm^2). PEX group without glaucoma showed endothelial cell density slightly higher than PEXG group (2286 ± 348 cells/ mm^2). Highest endothelial cell density was seen in CNT group (2513 ± 265 cells/ mm^2).

Research done by Inoue et.al, Seitz et. al and Wang et.al shows that ECD of PEX group without glaucoma was lower than that of CNT group which is similar to present study.^{9,10,11} (Table 3). Wali et. al studied ECD in PEX group without glaucoma and PEXG group whose results were similar to present study.¹²

Table 3: Result summary of research comparing endothelial cell density (ECD) of patient with PEX syndrome to the ECD of people without PEX syndrome and PEX to PEXG.

Authors	ECD PEX versus ECD CNT (cells/ mm ²)	p	ECD PEX versus ECD PEXG (cells/mm ²)	P
Inoue et.al ⁹	2336 ± 383 versus 2632 ± 327	0.003	2337 ± 407 versus 2332 ± 336	0.98
Seitz et.al ¹⁰	2052 ± 264 versus 2372 ± 276	<0.001	2214 ± 251 versus 2014 ± 254	0.08
Wang et.al ¹¹	2298 ± 239 versus 2652 ± 18	0.026	2505 ± 284 versus 2186 ± 2	0.278

Present study shows that PEX syndrome with and without glaucoma significantly reduces ECD. Pseudoexfoliation material is responsible for the reduction of ECD which settles on endothelium and later on penetrates into descemet's membrane causing breakage of connection between endothelial cells resulting in accelerated apoptosis. Other factors responsible for decrease in ECD were anterior chamber hypoxia, raised level of TGF- α 1 and endothelial fibroblast changes.^{3,13} Occurrence of glaucoma further accelerates the damage of endothelial cells. When ECD reduced to <800 cells/mm² it causes corneal decompensation leading to corneal oedema resulting in loss of translucency.¹⁴ Patients having ECD <2000 cells/mm² are considered to be high risk patients.¹⁵ ECD loss after intraocular surgery fluctuates between 6% and 19% one year from the date of procedure.^{8,16,17,18} To reduce this loss dispersive and adaptive viscoelastic substance should be used to maintain proper anterior chamber depth and to prevent instrument contact with endothelium.

Limitations of the present study:

- The severity of PEX was not accessed.
- Morphological analysis of corneal endothelial cells was not performed.
- Central corneal thickness was not compared in different groups.

Conclusion

ECD in PEX syndrome with and without glaucoma was statistically significantly lower than control group which may increase the risk of corneal decompensation after intraocular surgery. Difference of ECD in PEX and PEXG group was statistically insignificant.

Financial support and sponsorship: Nil.

Conflicts of interest: There are no conflicts of interest.

References

1. E. Forsman, R. M. Cantor, A. Lu et al., "Exfoliation syndrome: prevalence and inheritance in a subsample of the Finnish population," *Acta Ophthalmologica Scandinavica*, vol. 85, no. 5, pp. 500-507, 2007.
2. A. Kurowska, A. Kaminska, J. Izdebska, J. P. Szaflik, and J. Szaflik, "Zespoł pseudoeksfoliacji (PEX)-schorzenie 'ogólnoustrojowe,'" *Klinika Oczna*, vol. 111, no. 4-6, pp. 160-164, 2009.
3. U. Schlotzer-Schrehardt and G. O. Naumann, "Ocular and " systemic pseudoexfoliation syndrome," *The American Journal of Ophthalmology*, vol. 141, no. 5, pp. 921-933, 2006.
4. Quiroga L, Lansingh VC, Samudio M, Peña FY, Carter MJ. Characteristics of the corneal endothelium and pseudoexfoliation syndrome in patients with senile cataract. *Clin Experiment Ophthalmol*. 2010;38(5): 449-455.
5. G. O. H. Naumann and U. Schlotzer-Schrehardt, "Keratopathy " in pseudoexfoliation syndrome as a cause of corneal endothelial decompensation," *Ophthalmology*, vol. 107, no. 6, pp. 1111-1124, 2000.
6. L. Ludwisiak-Kocerba, A. Hevelke, and D. Kęcik, "Zespół ' pseudoeksfoliacji – etiopatogeneza i objawy kliniczne," *Klinika Oczna*, vol. 108, no. 1-3, pp. 82-86, 2006.
7. Ritch R, Schlötzer Schrehardt U, Konstas AGP. Why is glaucoma associated with exfoliation syndrome? *Prog Retin Eye Res* 2003;22(3):253-275.
8. W. M. Bourne and J. W. McLaren, "Clinical responses of the corneal endothelium," *Experimental Eye Research*, vol. 78, no. 3, pp. 561-572, 2004.
9. K. Inoue, K. Okugawa, T. Oshika, and S. Amano, "Morphological study of corneal endothelium and corneal thickness in pseudoexfoliation syndrome," *Japanese Journal of Ophthalmology*, vol. 47, no. 3, pp. 235-239, 2003.
10. B. Seitz, E. E. Muller, A. Langenbacher, M. M. Kus, and G. O. H. Naumann, "Endothelial keratopathy in pseudoexfoliation syndrome: quantitative and qualitative morphometry using automated video image analysis," *Klinische Monatsblätter für Augenheilkunde*, vol. 207, no. 3, pp. 167-175, 1995.
11. M. Wang, W. Sun, and L. Ying, "Corneal endothelial cell density and morphology in Chinese patients with pseudoexfoliation syndrome," *International Journal of Ophthalmology*, vol. 5, no. 2, pp. 186-189, 2012.
12. U. K. Wali, A. S. Al-Mujaini, N. S. Al-Kharusi, A. A. Bialasiewicz, and S. G. Rizvi, "Quantitative

- and qualitative corneal endothelial morphology of omani patients with pseudoexfoliation syndrome," Sultan Qaboos University Medical Journal, vol. 8, no. 3, pp. 300-305, 2008.
13. G. O. Naumann, U. Schlotzer-Schrehardt, and M. K. Uchle, "Pseudoexfoliation syndrome for the comprehensive ophthalmologist. Intraocular and systemic manifestations," *Ophthalmology*, vol. 105, no. 6, pp. 951-968.
 14. T. Olsen and J. S. Eriksen, "Corneal thickness and endothelial damage after intraocular lens implantation," *Acta Ophthalmologica*, vol. 58, no. 5, pp. 773-786, 1980.
 15. L. Quiroga, C. van Lansingh, M. Samudio, F. Y. Pena, and M. J. Carter, "Characteristics of the corneal endothelium and pseudoexfoliation syndrome in patients with senile cataract," *Clinical and Experimental Ophthalmology*, vol. 38, no. 5, pp. 449-455, 2010.
 16. H. B. Dick, T. Kohnen, F. K. Jacobi, and K.W. Jacobi, "Long-term endothelial cell loss following phacoemulsification through a temporal clear corneal incision," *Journal of Cataract and Refractive Surgery*, vol. 22, no. 1, pp. 63-71, 1996.
 17. T. Walkow, N. Anders, and S. Klebe, "Endothelial cell loss after phacoemulsification: relation to preoperative and intraoperative parameters," *Journal of Cataract & Refractive Surgery*, vol. 26, no. 5, pp. 727-732, 2000.
 18. W. M. Bourne, L. I. L. Nelson, and D. O. Hodge, "Central corneal endothelial cell changes over a ten-year period," *Investigative Ophthalmology and Visual Science*, vol. 38, no. 3, pp. 779-783, 1997.
-