

---

## Challenges of Complicated Enterocutaneous Fistulas

**Sudershan Kapoor**

**Author Affiliation:** Professor, Department of Surgery, Government Medical College, Amritsar, Punjab 143001.

**Reprint Request:** Sudershan Kapoor, Professor, Department of Surgery, Government Medical College, Amritsar, Punjab 143001

E-mail: drskapoor008@yahoo.co.in

---

### Abstract

Enterocutaneous Fistulas are a common presentation in general surgical wards, and despite advances in the management of these lesions, they are still responsible for a significant mortality rate, ranging from 5-20%, due to associated sepsis, nutritional abnormalities, and electrolyte imbalance. Enterocutaneous fistulas are more commonly seen in post-operative setting. An enterocutaneous fistula (ECF) is a potentially catastrophic postoperative complication. It seems prudent, then, for every surgeon to have a thorough grasp of optimal treatment strategies for ECF to minimize their patients' mortality. Ultimately, the algorithm must begin with prevention. Morbidity associated with fistulas is significant; the principle cause of death are sepsis and malnutrition [9]. Special mention is given in this article to complicated fistulas such as those with high output, abdominal sepsis and large abdominal defects. There is stress on diversion of fecal matter through ileostomy at a normal site of intestines at a distance of fistula site and damage/devitalized and inflamed gut (Proximal loop ileostomy) and fistula repair at comparatively early stage to prevent the further complications of sepsis and malnutrition. This plan gives a framework for the difficult task of successfully treating the postoperative ECF with a multidisciplinary approach.

**Keywords:** Enterocutaneous Fistula; Nutritional Support; Sepsis; Proximal Loop Ileostomy.

---

### Introduction

Enterocutaneous fistulas (ECF) present as devastating complications following postoperative abdominal surgery and as secondary manifestations due to primary intra-abdominal pathologic processes. Management challenges focus on fluid resuscitation, nutritional supplementation, electrolyte replenishment, control of sepsis, containment of effluent, skin integrity and surgery. Patient and family remain integral to the plan of care, as their physical and psychological challenges will be many.

Particularly difficult are complicated fistulas of those associated with large abdominal defects. Mortality rates in these cases may reach 60%-80%. The current treatment of intestinal fistulas coupled with a multidisciplinary approach has helped to

decrease the mortality rate to 15-30%.

Earlier study suggests that about 95% of ECFs were postoperative and ileum was found to be the most common site of ECF [1]. Forty-nine percent of fistulas were high output and 51% were low output.

Enterocutaneous fistulas (ECFs) can occur as a complication following any type of surgery on the GI tract. Indeed, more than 75% of all ECFs arise as a postoperative complication, while about 15-25% of them result from abdominal trauma or occur spontaneously in relation to cancer, irradiation, inflammatory bowel disease, or ischemic or infective conditions. The etiology of ECFs can thus be characterized as postoperative, traumatic, or spontaneous [3].

#### *Postoperative Causes*

Postoperative causes of ECFs include the following:

- Disruption of anastomosis
- Inadvertent enterotomy - Especially occurs in patients with adhesions, when dissection can cause multiple serosal tears and an occasional full-thickness tear
- Inadvertent small bowel injury - Occurs during abdominal closure, especially after ventral hernia repair, malnutrition.

Enterocutaneous fistula (ECF), a special subset of ECF, is defined as a communication between the gastrointestinal (GI) tract and the atmosphere. It can occur as a complication of "damage control" laparotomy (DCL) and results in significant morbidity and mortality [5]. Their etiology is complex and ranges from persistent abdominal infection, anastomotic dehiscence, and adhesions of the bowel to fascia with a laparostomy. As EAFs almost never close spontaneously, definitive repair usually requires major surgical intervention [8].

Disruption of anastomosis can result from inadequate blood flow due to an improper vascular supply, especially when extensive mesenteric vessels have to be ligated. Tension on anastomotic lines following colonic resection, restoration of continuity without adequate mobilization, or a minimal leak or infection can lead to perianastomotic abscess formation, resulting in disruption, as seen in patients with anterior resection for rectal carcinoma. In addition, if anastomosis is performed in an unhealthy bowel (eg, diseased, ischemic), it can lead to disruption and cause an ECF.

Inadvertent picking up of the bowel during abdominal closure can result in a small-bowel fistula; this especially can occur with the use of open inlay mesh or intraperitoneal inlay mesh repair by the laparoscopic method, when the viscera comes in contact with the mesh, leading to adhesions and sometimes to disruption

#### Output of the Fistula

The type of ECF, as based on the output of the enteric contents, also determines the patient's health status and how the patient may respond to therapy. ECFs are usually classified into 3 categories, as follows<sup>[2]</sup>:

- Low-output fistula (< 200mL/day),
- Moderate-output fistula (200-500mL/day)
- High-output fistula (>500mL/day)

A high-output fistula increases the possibility of fluid and electrolyte imbalance and Etiology.

Type I ECF originate from esophageal, gastric and duodenal sources;

Type II from small bowel;

Type III from large bowel; and

Type IV from large abdominal wall defects greater than 20cm

#### *Favorable Factors for Spontaneous Closure*

Spontaneous closure of an ECF is determined by certain anatomic factors. Fistulas that have a good chance of healing include the following:

- End fistulas (eg, those arising from leakage through a duodenal stump after Pólygastrectomy)
- Jejunal fistulas
- Colonic fistulas
- Continuity-maintained fistulas - These allow the patient to pass stool
- Small-defect fistulas
- Long-tract fistulas

In addition, a fistulous tract of more than 2 cm has a higher possibility of spontaneous closure. Spontaneous closure is also possible if the bowel-wall disruption is partial and other factors are favorable. If the disruption is complete, surgical intervention is necessary to restore intestinal continuity.

#### *Unfavorable Factors for Spontaneous Closure*

When an ECF is associated with adverse factors, then spontaneous closure does not commonly occur, and surgical intervention, despite its associated risks, is frequently required. In these patients, the outcome is less likely to be good

Factors preventing the spontaneous closure of an ECF can be remembered by using the acronym FRIEND, which represents the following

- Foreign body
- Radiation
- Inflammation/infection/IBD
- Epithelialization of the fistula tract
- Neoplasm
- Distal obstruction - A distal obstruction prevents the spontaneous closure of an ECF, even in the presence of other favorable factors; if present, surgical intervention is needed to relieve the obstruction.

In addition, lateral duodenal, ligament of Treitz, and ileal fistulas have less tendency to spontaneously close.

### *Complicated Enterocutaneous fistulas*

- Complete distal intestinal obstruction.
- Adjacent infection or abscess.
- Fistulas associated with large abdominal wall defects.
- Fistulas associated with the loss of continuity of the gut
- Fistulas associated with the gut pathology.
- Fistular opening more than 2 cm .
- Continued high output from the fistula in spite of nothing orally and on continuous parenteral nutrition.
- Bleeding from the fistula.
- Epithelialised tracts.
- Adjacent foreign material like mesh or sutures.

### *Work up*

In addition to the routine haematological work up for management of fistula, some special investigations are required:

### *Fistulography*

Fistulography is conventionally performed 7-10 days after the presentation of an ECF and provides the following information:

- Length of the tract
- Extent of the bowel-wall disruption
- Location of the fistula
- Presence of a distal obstruction

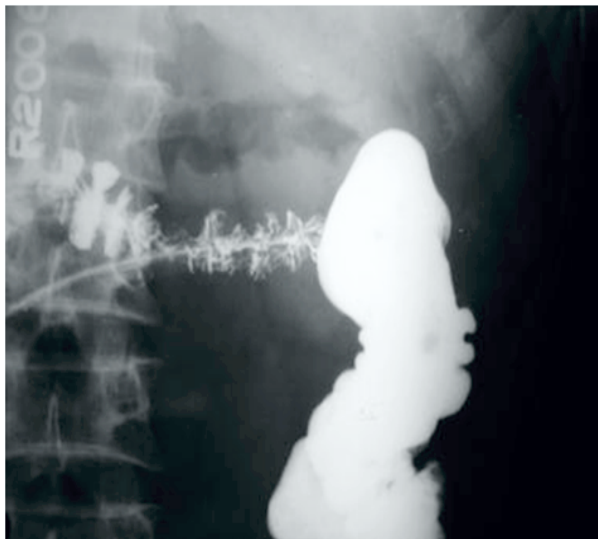


Image: Fistulogram showing the long tract of fistula

### *Water-Soluble Contrast Enema*

The different types of tracts that can be seen by using a water-soluble contrast enema (WCE) in patients with ECF with failure of low colorectal anastomosis may be classified as follows [16]:

- I - Simple, short blind ending, <2 cm
- II - Continuous linear, long single, >2 cm
- III - Continuous complex, multiple linear

### *Tract Positions are as Follows:*

- Anterior - Ventral, 10-o'clock to 2-o'clock position
- Posterior - Dorsal, 4-o'clock to 8-o'clock position
- Lateral - Right (2-o'clock to 4-o'clock position) or left (8-o'clock to 10-o'clock position)

Additional tract features seen with a WCE include the cavity (pooling of contrast within space) and/or a stricture (narrowing of anastomosis, with hold of contrast). The presence of a stricture and a large cavity on WCE predicts failure of healing.

### *Computed Tomography*

Computed tomography (CT) is useful for demonstrating intra-abdominal abscess cavities. Such cavities can occur if an ECF has an indirect tract when it first drains into an abscess cavity and then drains to the exterior cavity. If an ECF is associated with intra-abdominal sepsis, then interloop abscesses may be present.

### *Approach Considerations*

The conventional therapy for an enterocutaneous fistula (ECF) in the initial phase is always conservative. Immediate surgical therapy on presentation is contraindicated, because the majority of ECFs spontaneously close as a result of conservative therapy. Surgical intervention in the presence of sepsis and poor general condition would be hazardous for the patient.

However, patients with an ECF with adverse factors, such as a lateral duodenal fistula, an ileal fistula, a high-output fistula, or a fistula associated with a diseased bowel, may require early surgical intervention.

### *Role of Surgery*

Proximal diversion of fecal matter by making ostomies can reduce the complications related to continuous exposure to sepsis in complex fistulas.

Early surgical intervention is required in all complicated enterocutaneous fistulas. Nonsurgical therapy may allow for spontaneous closure of the fistulas, though this can be expected in less than 30% cases and that also depends upon the nutritional status of the patient, sepsis and underlying cause. Drainage of intraperitoneal abscesses, resection of devitalized parts, repair of the damaged parts of gut can be attempted at the same sitting along the proximal diversion. This avoids the subsequent laparotomies at a later stage. Closure of the ostomy can be done after 8-12 weeks when the general condition of the patient improves (never before 6 weeks) and healing of the distal segment of gut. After doing proximal ostomy, enteral nutrition can be started at the earliest. Early start of enteral nutrition decreases the bacterial translocation and the tropic effects on the intestinal mucosa.

#### *Aims and Objectives*

A prospective study of the role of early proximal loop ileostomies in cases of complicated enterocutaneous fistulas-A study of 80 cases (2005-2015).

#### **Material and Methods**

This study was conducted on 80 cases of complicated enterocutaneous fistulas, all were post-operative and majority were of high output type. After resuscitation and supportive management, early exploration was done. Resection of devitalized part, drainage of infected foci, repair of the damaged part of intestine and proximal loop ileostomy was done. Routine and other relevant investigations were done.

#### *Preparation of the Patient*

Surgical planning for fistula repair was individualised according to the pt's condition and intra-operative findings.

#### *Appropriate Pre-Operative Assessment Included*

1. Ensure that the patient is euvolemic.
2. Blood transfusions and TPN as required.
3. Proper coverage of antibiotics.
4. Central venous line
5. Foley's catheterization

#### *Intra-Operative Findings*

During exploration, following points were noted:

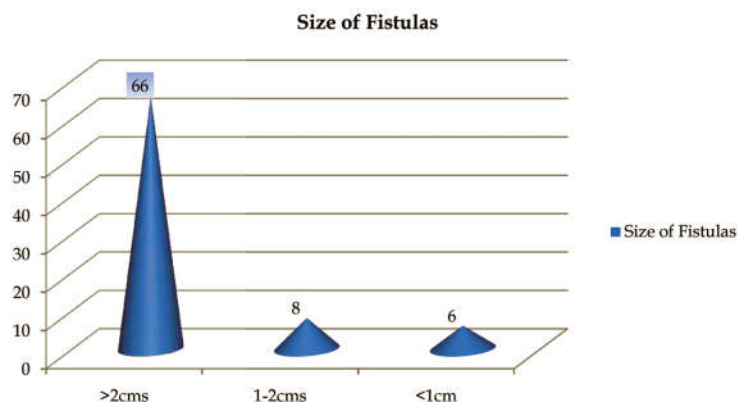
1. Collection in peritoneal cavity.
2. Site, size and number of fistulas.
3. Condition of gut.
4. Intra peritoneal and interloop abscesses.
5. Any evidence of obstruction distal to fistula
6. Condition of other viscera

#### *Procedure Done*

- Drainage of collections.
- Exploration, lysis of adhesions and mobilisation of the entire gut.
- Resection of devitalised part.
- Repair of the fistular segments or resection anastomosis in single layer with interrupted non absorbable sutures.
- Proximal loop ileostomy (PLI) from the comparatively healthy part of gut( at least 30 -40 cm from the damaged/ inflamed/ diseased gut).
- Abdominal drain in pelvis.
- Closure of the main wound in two layers

#### *Observations*

- AGE INCIDENCE: 10-50 yrs (Majority 20-40 yrs).
- SEX INCIDENCE: Males:57  
Females:23
- FISTULA OUTPUT: High output: = 60 cases  
Low output: = 20 cases
- ETIOLOGY : Post-operative



**Fig. 1:** Size of fistula

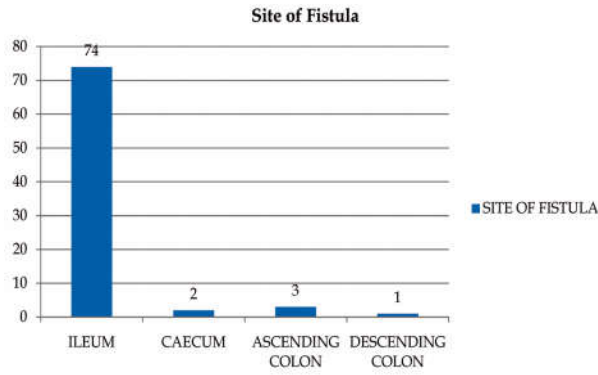


Fig. 2: Site of Fistula

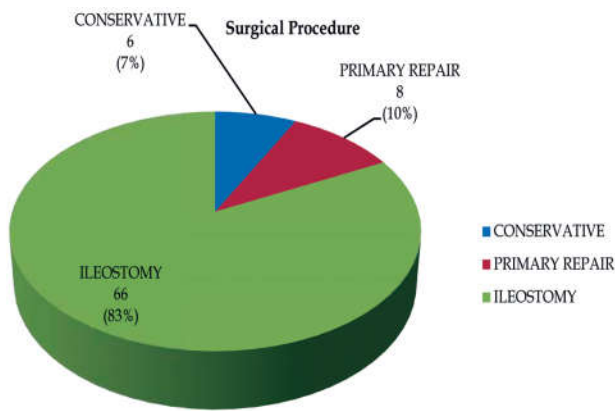


Fig. 3: Surgical Procedures done in the study

Re - Exploration After Primary Repair	: 6 cases ( All in which primary repair was done )
Ileostomy Closure ( After 8-10 weeks )	: 66 cases
Post Operative Wound Infection	: 31 cases
Post Operative Wound Dehiscence	
Complete	: 1
Incomplete	: 19
Follow Up ( Any Faecal Discharge After Ileostomy Closure )	: Only 1 case having small amount of faeculant discharge with normal bowel habit. - Managed conservatively
Peri-Operative Mortality	: 9 cases ( due to septicaemia )

Fig. 4: Table of Results of the study

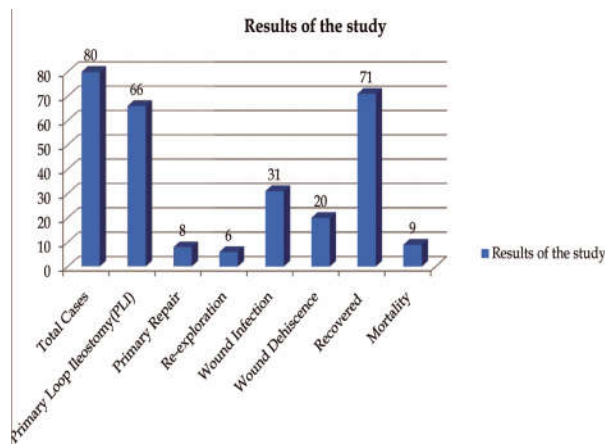


Fig. 5: Chart showing Results of the study

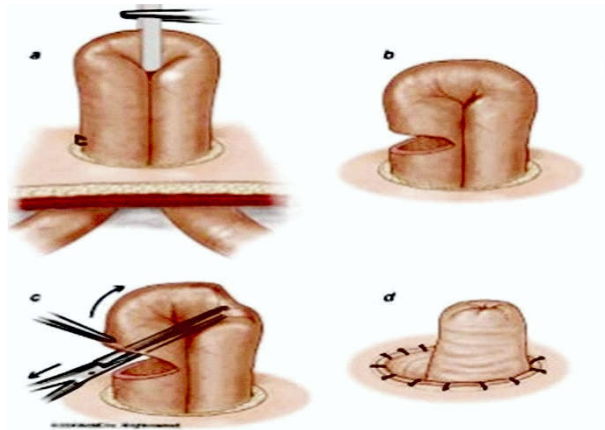


Fig. 6: Technique of ileostomy

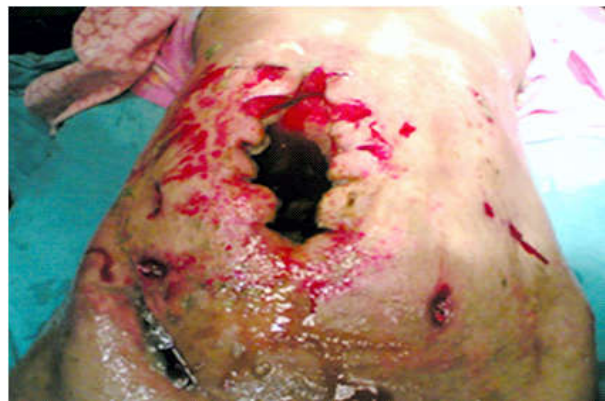

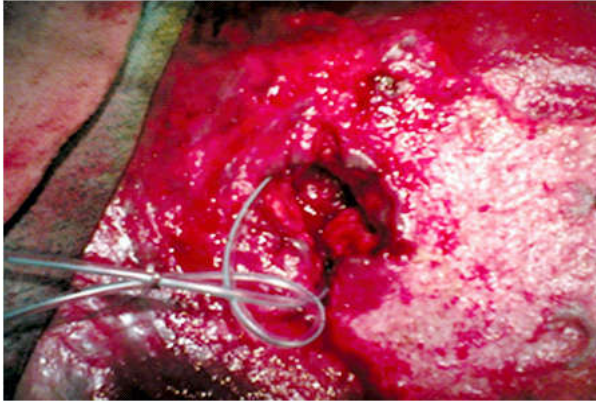
Fig. 7: Enterocutaneous Fistula Case-1

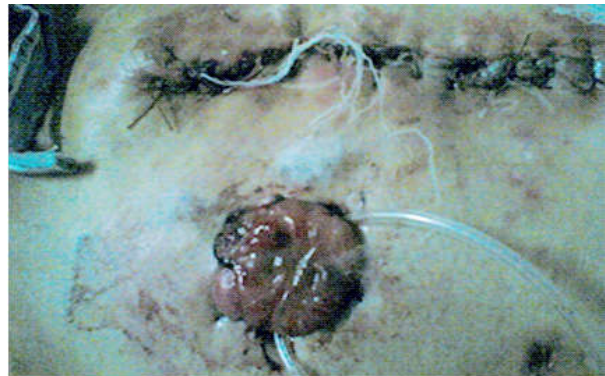

Fig. 8: Fistula Repaired And Proximal Loop Ileostomy Done...Case-1

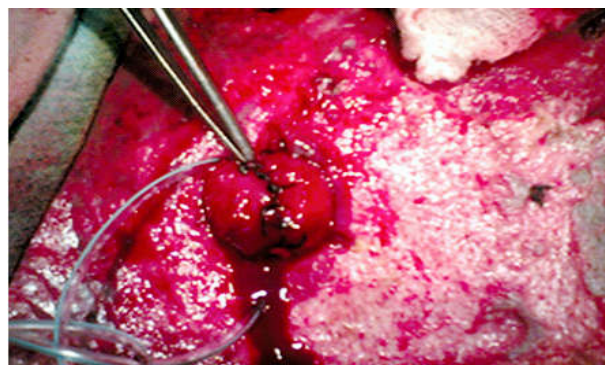

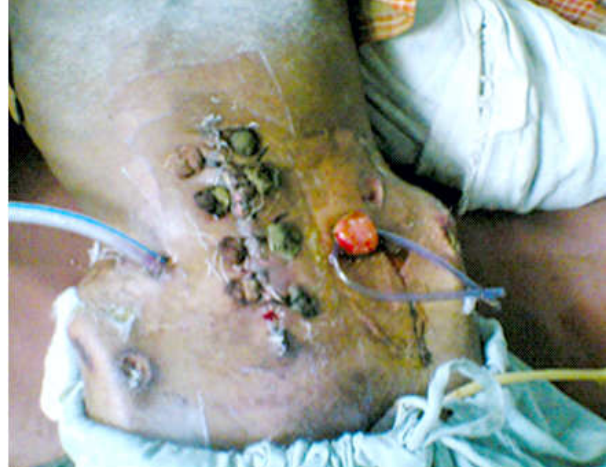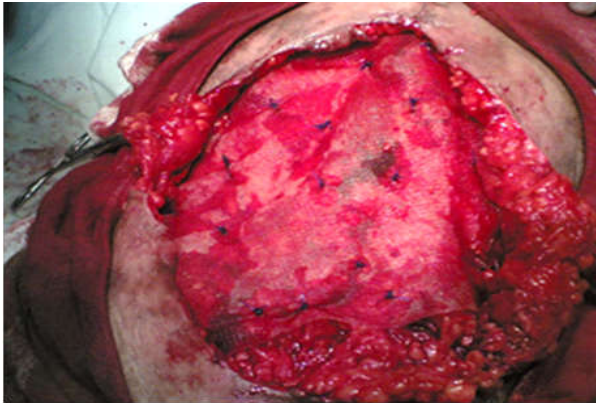
Fig. 9: Ileostomy Closed And Loop Kept Outside To See For Leakage..Case-1



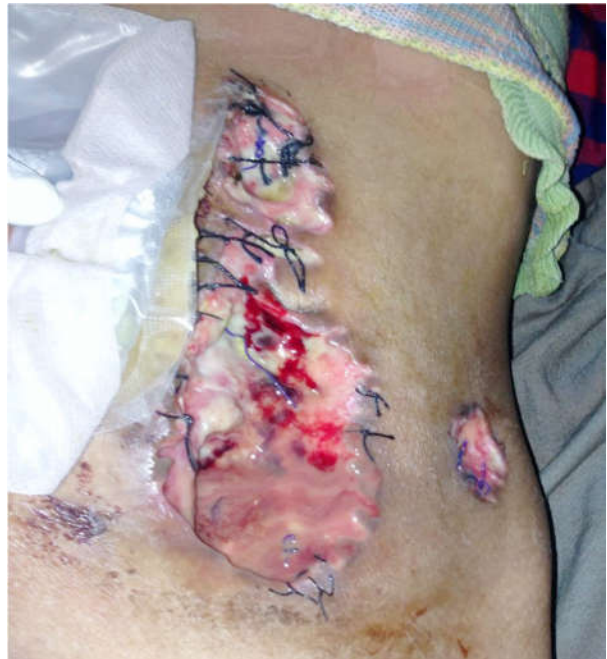**Fig. 10:** Closed Ileostomy Put Inside Peritoneal Cavity But With Catheter Support . Case-1



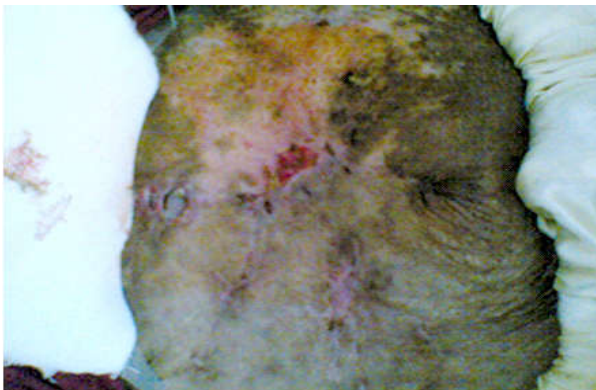**Fig. 14:** Fistula Repaired with Proximal Loop Ileostomy Case-2



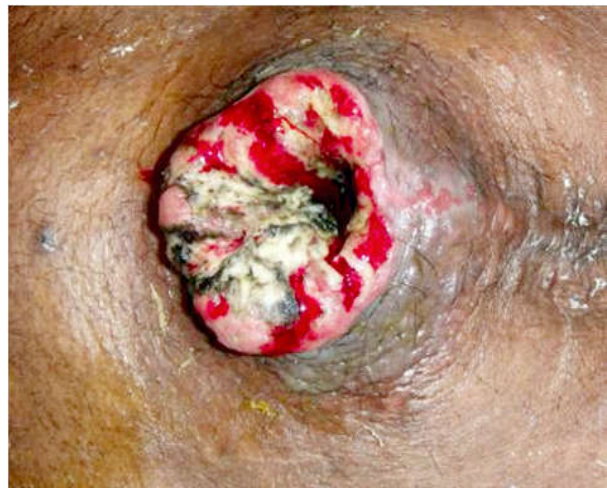**Fig. 11:** Patient Had Burst Abdomen. Abdominal Wound Closed With Mesh Interposition And To Wait For Healing By Secondary Intention. Case-1



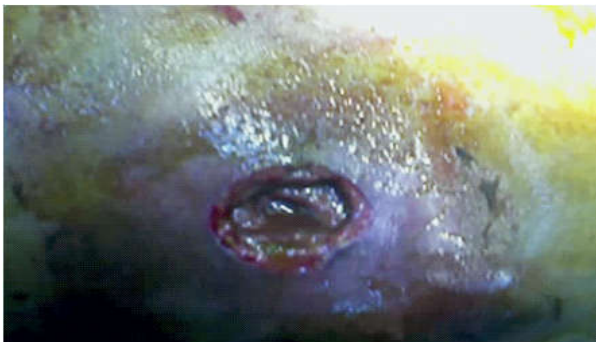**Fig. 15:** Post operative Enterocutaneous fistula



**Fig. 12:** Completely Healed Wound .Case-1



**Fig. 16:** Showing Wound Dehiscence



**Fig. 13:** Enterocutaneous Fistula Case-2

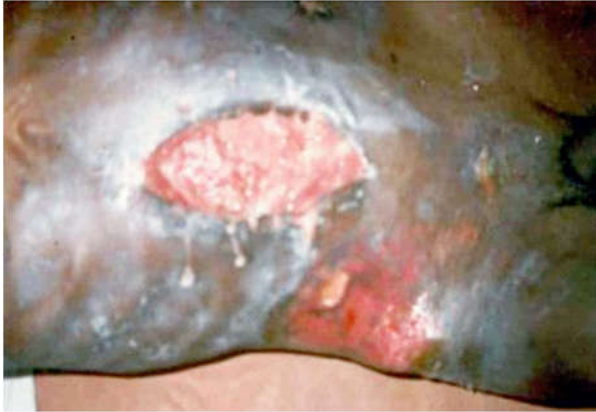

Fig. 17: Showing Excoriation of Surrounding Skin

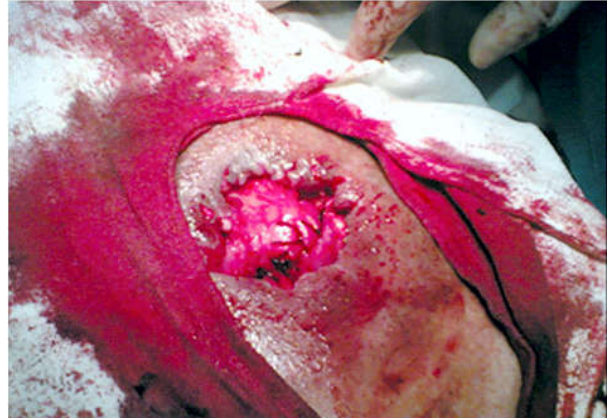


Fig. 21: Wound With Fistula Repaired. Case-3

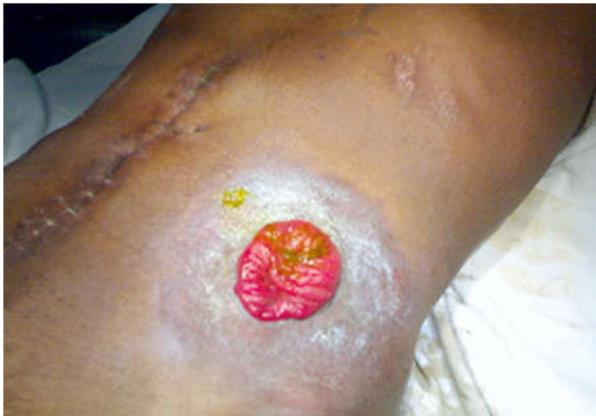

Fig. 18: Wound Healed. Ileostomy Working. Case-2

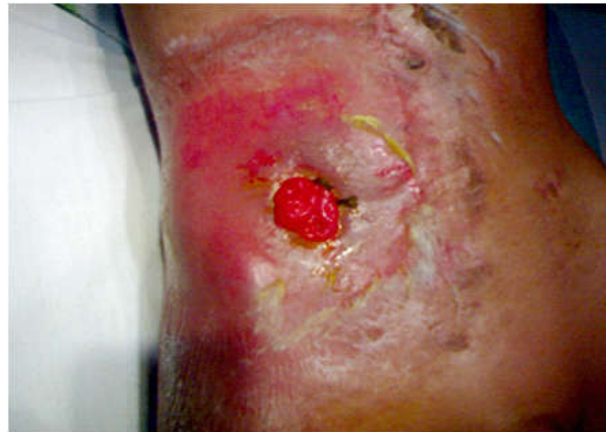

Fig. 22: Healed Abdominal Wound With Ileostomy. Case-3

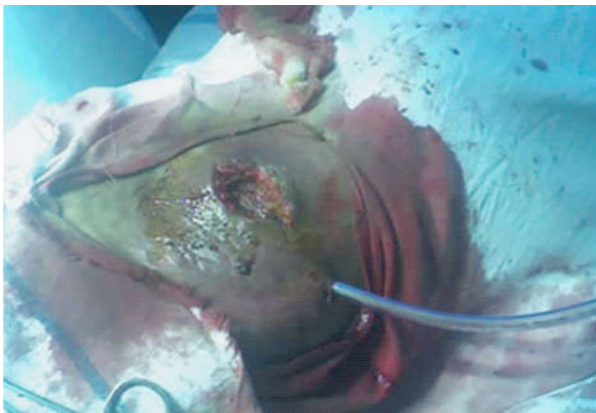

Fig. 19: Enterocutaneous Fistula With Drain In Peritoneal Cavity. Case-3

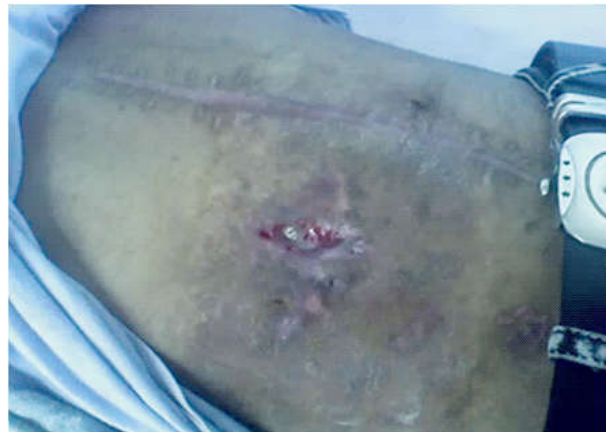

Fig. 23: Completely Healed Wound After Ileostomy Closure. Case-3

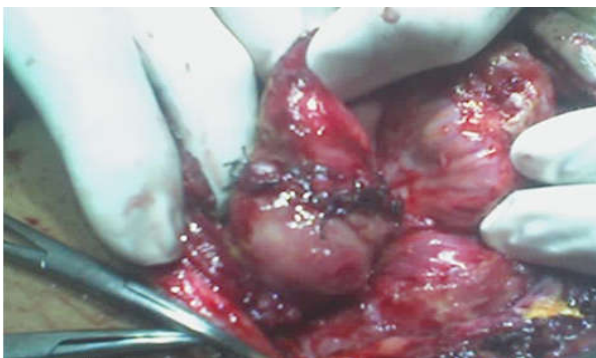

Fig. 20: Fistular Site Repaired. Case-3

### Discussion

- In our study, majority of the patients presented with complicated type of enterocutaneous fistulas.
- In 66 out of 80 cases, exploration with drainage of intra-peritoneal collections, resection of the devitalized part and repair of the gut was done and proximal loop ileostomies were created.

- These patients did well post operatively without any major post-operative complications in most of the cases.
- Those 6 cases in whom primary repair was done, had to be re-explored and treated on the same line of proximal loop ileostomy. They also responded well post-operatively except 9 cases (died during the course of treatment).
- Proximal loop ileostomy (P L I) with repair of the damaged part of gut showed good results and less morbidity and mortality in the present study.
- P L I also avoids re-laparotomies at later stages as ileostomy closure can be carried out by exploring the same area of ileostomy site.
- P L I is better than exteriorization of the fistula segments as that part of gut is badly inflamed adherent and has septic focus, so more chances of ileostomy related complications.
- P L I provides sufficient time for the healing of repaired part of gut and inflammation of adjacent loops of gut to settle down.

### Conclusion

- Our study concludes that in cases of complicated entero-cutaneous fistulas, early proximal loop ostomies/ileostomies along with the repair of fistula sites gives good results and less morbidity and mortality.
- This procedure can be considered in the management of complicated entero-cutaneous fistula.
- Medical and nursing care demand a complementary, interdisciplinary approach if successful closure of an enterocutaneous fistula is to be achieved. The patient and family are challenged by physical and psychological stressors, which often result in weeks and even

months of hospitalization. As health-care practitioners, we must remember to treat the patient as a whole person and not just 'as a hole.' The fistula should not become the only focus of care, but rather an element of the overall treatment plan.

### References

1. Kumar P, Maroju NK, Kate V. Enterocutaneous fistulae: etiology, treatment, and outcome - a study from South India. *Saudi J Gastroenterol.* 2011 Nov-Dec; 17(6): 391-5.
2. Berry SM, Fischer JE. Classification and pathophysiology of enterocutaneous3. fistulas. *Surg Clin North Am.* 1996 Oct; 76(5): 1009-18.
3. Edmunds LH Jr, Williams GH, Welch CE. External fistulas arising from the gastro-intestinal tract. *Ann Surg.* 1960 Sep; 152: 445-71.
4. Fischer PE, Fabian TC, Magnotti LJ, et al. A ten-year review of enterocutaneous fistulas after laparotomy for trauma. *J Trauma.* 2009 Nov; 67(5): 924-8.
5. Falconi M, Sartori N, Caldiron E, et al. Management of digestive tract fistulas. A review. *Digestion.* 1999; 60(Suppl 3): 51-8.
6. Evenson AR, Fischer JE. Current management of enterocutaneous fistula. *J Gastrointest Surg.* 2006 March; 10(3): 455-64.
7. Tong CY, Lim LL, Brody RA. High output enterocutaneous fistula: a literature review and a case study. *Asia Pac J Clin Nutr.* 2012; 21(3): 464-9.
8. Campos AC, Andrade DF, Campos GM, et al. A multivariate model to determine prognostic factors in gastrointestinal fistulas. *J Am Coll Surg.* May 1999; 188(5): 483-90.
9. Reber HA, Roberts C, Way LW, et al. Management of external gastrointestinal fistulas. *Ann Surg.* 1978 Oct; 188(4): 460-7.
10. Draus JM Jr, Huss SA, Harty NJ, et al. Enterocutaneous fistula: are treatments improving?. *Surgery.* Oct 2006; 140(4): 570-6; discussion 576-8.