

Age estimation in anthropology: some case histories



University of Pisa

Department of Oncology, Transplants and Advanced Technologies in Medicine

Division of Paleopathology

AGE ESTIMATION

"State of the art, guidelines and new projects"

Institute of Legal Medicine, University of Macerata

5-6 October 2007

Gino Fornaciari
Marielva Torino

The Medici was one of the most powerful families of the Italian Renaissance. Starting from the 14th century, their careful management of banking ventures and skilful political actions brought them to the forefront of social and political power in Tuscany and in Florence, the intellectual center of the Western world.

Lovers of art and science, the Medici were patrons of Michelangelo, Leonardo da Vinci, Botticelli, Galileo, and Benvenuto Cellini.

There are two main branches in the Medici family tree: the branch of Lorenzo the Magnificent (1446-1492), and the branch of the Grand Dukes of Tuscany, which began with John of the Black Bands (1498-1526) and ended with Gian Gastone (1671-1737), the last Grand Duke. The most important members of this impressive dynasty were buried under the vaults of the Basilica of San Lorenzo in Florence.

In 2002, Dr. Antonio Paolucci, Superintendent of Florentine Museums, granted permission to examine 49 of the Medici burials in the Basilica.

The research programme includes funerary archeology, physical anthropology,

paleonutrition, parasitology, pathology, histology, histochemistry, immuno-histochemistry, electron microscopy, molecular biology, and identification of ancient pathogens.

In order to conduct this study, we set up a temporary laboratory in the Lorena Chapel, the funerary crypt of the Grand Dukes of the Lorena dynasty, which ruled Florence and Tuscany after the Medici until 1859.

We decided to begin our examination with the intact tomb of Gian Gastone (1671-1737), the last Grand Duke of the Medici.

Under the slab of marble with his epigraph was nothing but the removal of a plain dark marble disk in the floor of the chapel with no epigraph, considered a simple floor decoration, displayed a secret opening with a small stone stair leading to a hidden crypt.

A low raised platform running around the base of the crypt's walls supported a large sarcophagus and many small wooden coffins; these coffins had completely collapsed on the floor, covered by a layer of dry mould from the disastrous flood of 1966.

The large wooden sarcophagus belonged to Grand Duke Gian Gastone and the outer part of it apparently was well preserved but it was in fact very fragile, because of the high level of humidity.

The lid of the sarcophagus, badly damaged, had collapsed into the interior revealing the inner coffin of lead, with a large Christian cross and six iron handles on the lid.

The body of the Grand Duke was intact: he

Author's Affiliations: Medical School

Via Roma, 57
56126 Pisa, Italy

Reprints Request: Dr. Gino Fornaciari

Medical School
Via Roma, 57, 56126 Pisa, Italy

Received on 16 April, 2009, Accepted on 15 July, 2009

was covered by the silk Great Cape (*Cappa Magna*) of the Grand Master of Knights of the Order of St Stephen and was still wearing his funerary crown.

Other small coffins of children, collapsed on the floor or variously distributed on the raised floor level, were visible in the crypt and the recovery of some parts of the same individual in different positions clearly indicates the movements of the coffins and bodies during the flooding in Florence.

Contrary to all expectations, several of the burials in the small wooden coffins were fairly intact.

The elaborate costume of a 5-year-old child, consisted of a red silk jacket with a thin collar and buttons adorned with silver gallons and large plus-fours in the same flowery fabric, complete with shoes and silver crown, showed an excellent state of preservation.

The costume is very similar to that worn by Don Filippino (1577-1582), a young son of the Grand Duke Francesco I, portrayed with his mother, the Grand Duchess Giovanna from Austria.

Other burials as, for example, the one of a baby of about 9 months, dressed in a precious silk vest with silver cuffs, resulted less well preserved.

METHODS

To study this sample, we used Schour and Massler, Ubelaker, and the Logan and Kronfeld modified by McCall and Schour evaluation tables based on the levels of maturity of the teeth.

The use of a portable radiovideographic device, a Kodak RVG which we took inside the Chapels, enabled us to do an x-ray analysis of the unemerged teeth and to establish the degree of maturity of the roots of teeth which had already emerged.

This meant that things could be done more quickly and the bodies did not have to be moved.

We deliberately chose not to carry out any kind of analysis which would have damaged the samples.

This dental investigation proved interesting

because, as in a double blind trial, once the child had been identified we were able to go back and look at the real time of death. Thus we could see the inherent strengths and weaknesses in the tables used to work out a child's age from the development of the teeth.

TOMB MED 40.29 ("CHILD WITH APRON")

$$DF: \frac{\quad + \quad}{V \quad - \quad V6}$$

- Schour and Massler : 9 months ± 2 months
- Ubelaker : 9 months ± 3 months
- Logan and Kronfeld : 9 - 10 months
- Skeletal age : 6 months

Comment

In this case, the dental age is slightly older than the skeletal age and we suspected rickets.

Historical data suggests that it could be the body of D. Pedricco, son of Cosimo I and Eleonora di Toledo, born in August 1546 and died on 9 June 1547 at 9 months of age; or Isabella, daughter of Francesco I and Giovanna of Austria, born on 30 September 1571 and died on 8 August 1572 at 9 months of age.

Historical documents dating back to the period make no mention of the death of any child in the Medici family at the age of six months, which is the estimated skeletal age.

TOMB MED 40.39 ("CHILD WITH RED JACKET")

$$DF: \frac{\overset{6}{V} \text{ IV } p \text{ II } p + p \text{ p III IV } \overset{6}{V}}{\underset{7 \ 6}{V} \text{ IV III II I } - \text{ I } p \text{ III IV } \underset{6 \ 7}{V}}$$

- Schour and Massler: 5 years ± 9 months
- Ubelaker: 5 years ± 16 months
- Logan and Kronfeld: 6 years
- Skeletal age: 6 - 7 years

Comment

In this case the skeletal age is set slightly above that of the dental age.

The dental data is based on the extent to which the 6s have come through and the maturity of the lower 7s.

There are enamel irregularities on the crowns (moruliform) of the lower 6s (fig.n.1) similar to those of -8 of Giovanna of Austria (Med 8).

This dental feature, recognised as being epigenetic, immediately gave us a clue of the person's identity and led us to suspect that it was Filippo, seventh child and only son of Francesco I and Giovanna of Austria, born on 20 May 1577 and died on 29 March 1582.

Historical accounts tell us that the young prince underwent an autopsy and that the skullcap was cut and removed, and that he was buried in "*a red velvet gown that reached down to his feet*" (Pieraccini, 1986). The body does, in fact, show signs of the skullcap being cut and removed while the "*gown...to his feet*" probably refers to a cloak which got destroyed.

Another element which was instrumental in identifying the boy was the red jacket he was wearing when he was found. It was the same as that worn by the young prince in one of his portraits and thus lends weight to the identification.

As far as Filippo is concerned, dental age, especially those calculated using the Schour and Massler, and Ubelaker methods, coincide with what would be the real age of the individual and thus proved more reliable than the skeletal values.

TOMB MED 40.40

$$\text{FD: } \frac{\begin{array}{ccccccc} & 3 & & & 3 & & \\ & \text{IV} & \text{p} & \text{II} & \text{I} & + & \text{I} & \text{p} & \text{p} & \text{IV} & \\ \hline & \text{IV} & \text{p} & \text{p} & \text{p} & - & \text{I} & \text{II} & \text{III} & \text{IV} & \text{V} \\ & 6 & 3 & & & & & & & & 6 \end{array}}{}$$

Schour and Massler:	18 months \pm 3 months
Ubelaker:	24 months \pm 8 months
Logan and Kronfeld:	16 months
Skeletal age:	18 months

Comment

In this case the skeletal age is more or less the same as the dental age, but we have two children who both died around that age. It could either be Lucrezia, daughter of Francesco I and Giovanna d'Austria, born on 7 November 1572 and died on 14 August 1574 at 22 months of age; or it could be Anna, daughter of Cosimo I and Eleonora di Toledo, born on 10 March 1552 and died on 6 August 1553 at 17 months of age (Pieraccini, 1986).

TOMB MED 40.1

$$\text{FD: } \frac{\begin{array}{ccccccc} & 6 & & 3 & & 2 & & 4 & & 6 \\ & \text{V} & \text{IV} & \text{III} & \text{II} & \text{I} & + & \text{I} & \text{p} & \text{III} & \text{IV} & \text{V} \\ \hline & \text{V} & \text{IV} & \text{III} & \text{II} & \text{I} & - & \text{I} & \text{II} & \text{III} & \text{IV} & \text{V} \\ & 7 & 6 & & & & & & & & & 6 & 7 \end{array}}{}$$

Schour and Massler:	3 years \pm 6 months
Ubelaker:	4 years \pm 12 months
Logan and Kronfeld:	2 and a half - 3 years
Skeletal age:	5 - 6 years

Comment

This is a very interesting case because there is discrepancy between the dental age and skeletal age and also between the different phases of development of the teeth. This means that it is impossible to determine the age of death precisely, even if using a single system.

Different values were recorded depending on the following elements:

Development of 4s: about 4 years according to the Schour and Massler method.

Development of 3s: about 5 years according

to the Ubelaker method.

Development of 6s: about 4 years \pm 12 months according to the Ubelaker method.

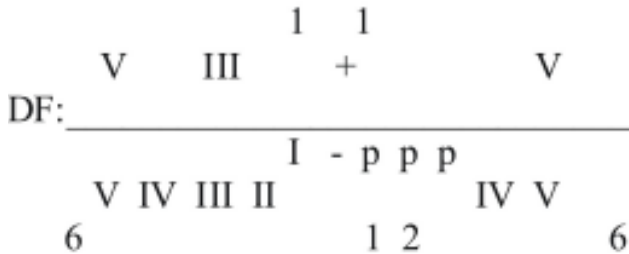
Development of 6s: about 4 years \pm 9 months according to the Schour and Massler method.

Roots of deciduous lower incisors: about 4 - 5 years according to the Logan and Kronfeld method.

Historical data tells us that it could be Filippo, fourth son and seventh child of Ferdinando I and Cristina di Lorena, born on 9 April 1598 and died on 3 April 1602, therefore at nearly four years of age (Pieraccini, 1986).

In this case, the skeletal age is significantly older, while the dental data obtained using the Ubelaker and Schour and Massler methods give us figures which are much closer to the real age. The reason for this could be a protein-rich diet with meat or beef tea which has stimulated the growth of the bones but not of the teeth.

TOMB MED 40.48



Schour and Massler: 9 months \pm 2 months or 12 months \pm 3 months

Ubelaker: 9 months \pm 3 months or 12 months \pm 4 months

Logan e Kronfeld: 7 months

The first figures are calculated on the basis of levels of maturity of the deciduous teeth while the second are based on the development of the teeth germs of the permanent teeth.

- Skeletal age : 6 - 12 months
- Humerus and femur : 6 -12 months
- Radius and tibia : 12 months

Comment

In this individual, there is again discrepancy between skeletal age and dental age.

We also found abnormalities in the levels of development of different teeth, which means that even when we use only one reference table to determine the age of death, the results can be different, depending on which particular teeth are analysed.

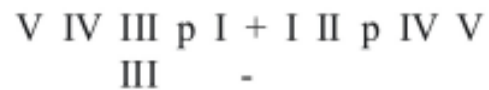
It is interesting to observe here how the permanent teeth demonstrate a level of maturity which would indicate a slightly older age than that suggested by the deciduous teeth. This obviously broadens the range of ages that can be attributed to the individual.

However, in this case there is also a difference in age, according to the bones studied.

As stated above, the historical data tells us that this could be D. Pedricco, son of Cosimo I and Eleonora di Toledo, born in August 1546 and died on 9 June 1547 at 10 months of age.

It could also be Isabella, daughter of Francesco I and Giovanna d'Austria, born on 30 September 1571 and died on 8 August 1572 at 11 months of age (Pieraccini, 1986).

TOMB MED 40.45



Schour and Massler: 7 months intrauterine - birth

Ubelaker: born \pm 2 months

Logan e Kronfeld: born (not more than 6 weeks old) - 7 months intrauterine

Skeletal age: newborn

Note

Most of the teeth were out.

The body could be that of Antonio, son of Cosimo I and Eleonora di Toledo, born on 1 July 1548, of whom there is little mention in the archives because he died shortly after birth.

It could also be Romola, daughter and second child of Francesco I and Giovanna of Austria, born on 20 November 1568 and died on 2 December after only twelve days of life. (Pieraccini, 1986).

TOMB MED 40.42.22

DF: IV germ +
-

SCHOUR AND MASSLER: 12 MONTHS \pm 3 MONTHS

Ubelaker: 12 months \pm 4 months

Logan and Kronfeld: - -

Skeletal age: 12 - 18 months

Comment

The only dental evidence to be found is a single tooth germ from a deciduous tooth, the IV+.

The case of this child is unusual. Only a few bones were found in Tomb 40 and these were not connected; they belonged to one or more people of a young age. They were located in two distinct areas and therefore were given two identification numbers: 22 and 42. Next to 42 there was also some material which has not yet been identified and which may have been put into the body when it was embalmed.

When we compared the morphology of the right and left humerus, each one found in different groups of bones, we discovered that they were similar in terms of size and shape, therefore we were able to find a relationship between them.

This made us realise that the bones belonged to only one person and that the body had been seriously disturbed during the flooding of Florence in 1966.

Only one dental element was found with the few bones in Med 42. It is a IV+ germ complete with crown but whose roots are not yet fully formed.

This could be the body of Anna, daughter of Cosimo I and Eleonora di Toledo, born on 10 March 1552 and died on 6 August 1553 at 17

months of age; or that of D. Pedricco, son of Cosimo I and Eleonora di Toledo, born in August 1546 and died on 9 June 1547 at 10 months of age; or Isabella, daughter of Francesco I and Giovanna of Austria, born on 30 September 1571 and died on 8 August 1572 at 11 months of age (Pieraccini, 1986).

Owing to overlap of the ranges of different anthropological methods, a positive identification of children is impossible on the basis of age.

IDENTIFICATION OF THE CHILDREN

	<u>Actual</u> age	<u>Dental</u> age	<u>Diaphysial</u> age	
<u>Sons of Francesco I</u>				
Lucrezia (1572-1574):	21 months	24 \pm 8 months	18 months	-> individual MED40.40
Don Filippo (1577-1582):	4 years & 10 months	5y. \pm 16 m.	6-7 years	-> individual MED40.39 "with the red jacket"
<u>Sons of Ferdinando I</u>				
Don Filippino (1598-1602):	4 years	4y. \pm 12 m.	5-6 years	-> individual MED40.1

CONCLUSIONS

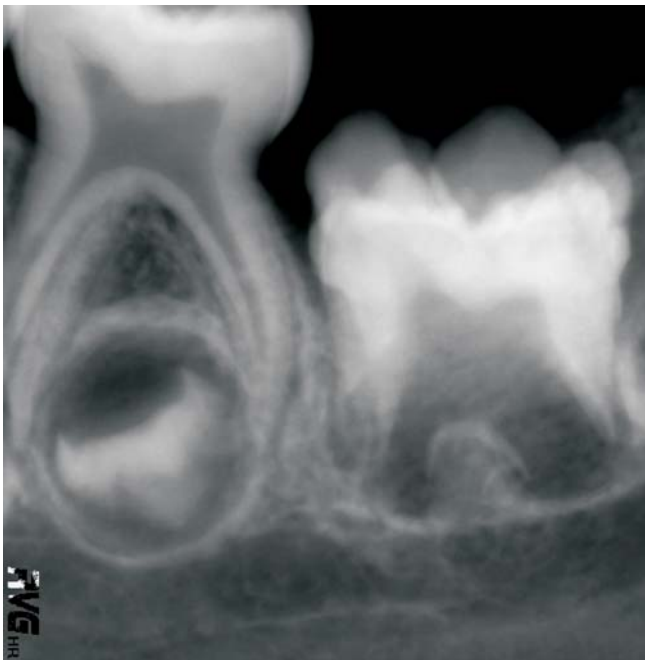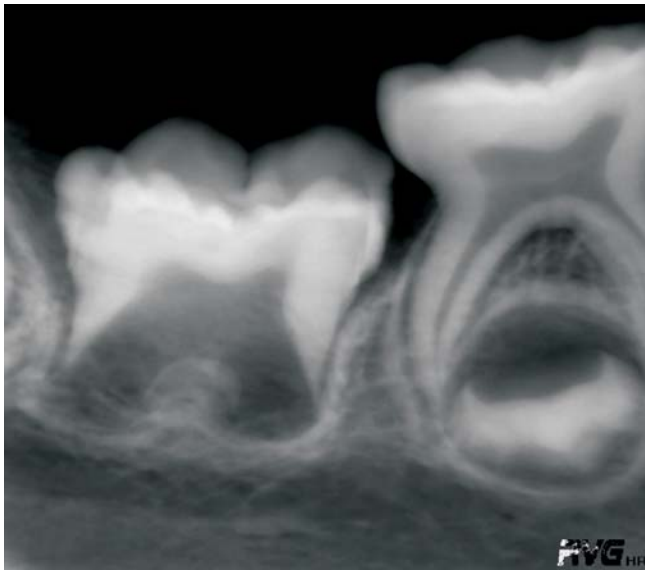The study we carried out on the younger members of the Medici family found in the tombs at the Medici Chapels of the Basilica of S. Lorenzo in Florence made us seriously reflect on the use of classic dental maturity reference tables to determine the age of death in a child.

However, in our opinion, considering how important it is for correct anthropological and paleopathological studies to establish the age of death, it is vital that different systems are compared and that more than one age indicator is used. In this way we can guarantee greater accuracy when evaluating the age of death of people of the past.

As stated by Steward (1962) the use of a single system can be reductive and not very reliable, not only in the adult population.

Therefore, we feel it is necessary to use more than one reference table and also to focus attention on the development of different teeth, even if this approach broadens the possible age range.

Fig. n.1: first lower left and right molars of MED40.39 ("Child with red jacket"): enamel irregularities on the crowns (moruliform teeth)



*We would like to thank Kodak for providing the equipment and the technicians, Mr. Giampiero Saibene, Gianluca Battipaglia and Marco Basani, and Mr. Roberto Modiano from Beraha Company - Naples.

1. Kronfeld, R.: *Development and calcification of the human deciduous dentition*. The Bur. 1935a; 15: 18-25.
2. Kronfeld, R. *First permanent molar: its condition at birth and its postnatal development*. Journal of the American Dental Association. 1935b; 22: 1131-1155.
3. Kronfeld, R. *Postnatal development and calcification of the anterior permanent teeth*. Journal of the American Dental Association. 1935c; 22: 1521-1536.
4. Kronfeld, R.; SCHOUR, I. *Neonatal dental hypoplasia*. Journal of the American Dental Association. 1939; 26: 18-32.
5. Logan, W.H.G.; Kronfeld, R. *Development of the human jaws and surrounding structures from birth to the age of fifteen years*. Journal of the American Dental Association. 1933; 20: 379-427.
6. Logan, W.H.G.: 1935. *A histological study of the anatomic structures forming the oral cavity*. Journal of the American Dental Association. 1935; 22: 3-30.
7. Massler, M.; Schour, I.; Poncher, H.: 1941. *Developmental pattern of the child as reflected in the calcification pattern of the teeth*. American Journal of Diseases of Children. 1941; 62: 33-47.
8. Pieraccini, G. *La stirpe De' Medici di Cafaggiolo*. Nardini Editore Firenze. 1986.
9. Schour, I; Massler, M. *The development of the human dentition*. Journal of the American Dental Association. 1941; 28: 1153-1160.
10. Stewart, T.D. *Comments on the reassessment of the Indian Knoll skeletons*. American Journal of Physical Anthropology. 1962; 20: 143-148.
11. Ubelaker, D.: 1978. *Human skeletal remains, excavation, analysis, interpretation*. Taraxacum, Washington.

REFERENCES