

What lay behind the mask of a neonatal tooth? An unusual case report

Shruthi B. Patil*
Rajesh T. Anegundi**
M. L. Wajapey***
Chaya S Mendon****

ABSTRACT

One of the current guiding principle of dentistry is to provide early infant care during the first year of life as a way of maintaining oral health. This is an unusual case report illustrating an intra oral mass on the gum pad of a 20 day old baby, which clinically mimicked neonatal tooth but was diagnosed to be an inflammatory abscess which could have led to septicemia. Clinical diagnosis of these conditions are important in order to provide necessary therapeutic procedure and suitable information to parents about the nature of the lesion and proper infant oral health care.

Key words: Neonate, Inflammatory abscess, Septicemia.

INTRODUCTION

The oral examination is an essential part of the routine physical examination of the newborn.¹ Many features of the infant's mouth are peculiar and unique to this period of development.² The oral lesions that present in newborn period include natal and neonatal teeth, clefts, dental lamina cyst, epstein pearls, bohn nodules, alveolar lymphangioma, Tumors (congenital epulis), ankyloglossia, geographic tongue, ranula, mucocele and congenital lip pits. Early examination can reveal abnormalities that require treatment or serve as baseline against which to compare later development and avoid undue emergencies.³ In the present case what looked like a neonatal tooth was found to be an inflammatory abscess; which on further neglect could lead to Septicemia.

Authors affiliations: *Associate Professor,**Prof & Head,*** Consultant Pediatrician, **** Post Graduate, Dept of Pediatric Dentistry, S.D.M. school of dentistry, Sattur, Dharwad, Karnataka.

Reprints Requests: Dr. Shruthi B. Patil. Associate Professor, Department of Pediatric Dentistry, S.D.M. College of Dental Sciences and Hospital, Sattur, Dharwad - 580009, Karnataka, India, Tel No: 9341841342, 836-2461830, Extn: 141, E-mail: shruthirajpatil@yahoo.co.in.

CASE REPORT

A 20 days old, baby boy was brought to Out Patient department, Dept of Paediatric Dentistry, SDM school of Dentistry, Dharwad, India by the parent with the complaint of presence of tooth in the upper right back region of the oral cavity. The parent also gave a history of poor feeding and crying during feeding.

Neonatal history was not contributory. Natal history revealed that delivery was uneventful. Baby was prematurely born at less than 37 week of gestation period. On physical examination performed shortly after delivery, the baby weighed 2.5 kg. The baby was healthy at birth. Prenatal history; on further enquiry, parent revealed that the baby had sustained a finger nail injury to his upper right gum pad caused by the care taker while cleaning.

On extra oral examination, baby also had a swelling of his right eye. A tense acute inflammatory swelling was found in the region of the lacrimal sac on the same side; there was oedema and erythema of the adjoining skin and eyelids associated with fever. (Figure 1)

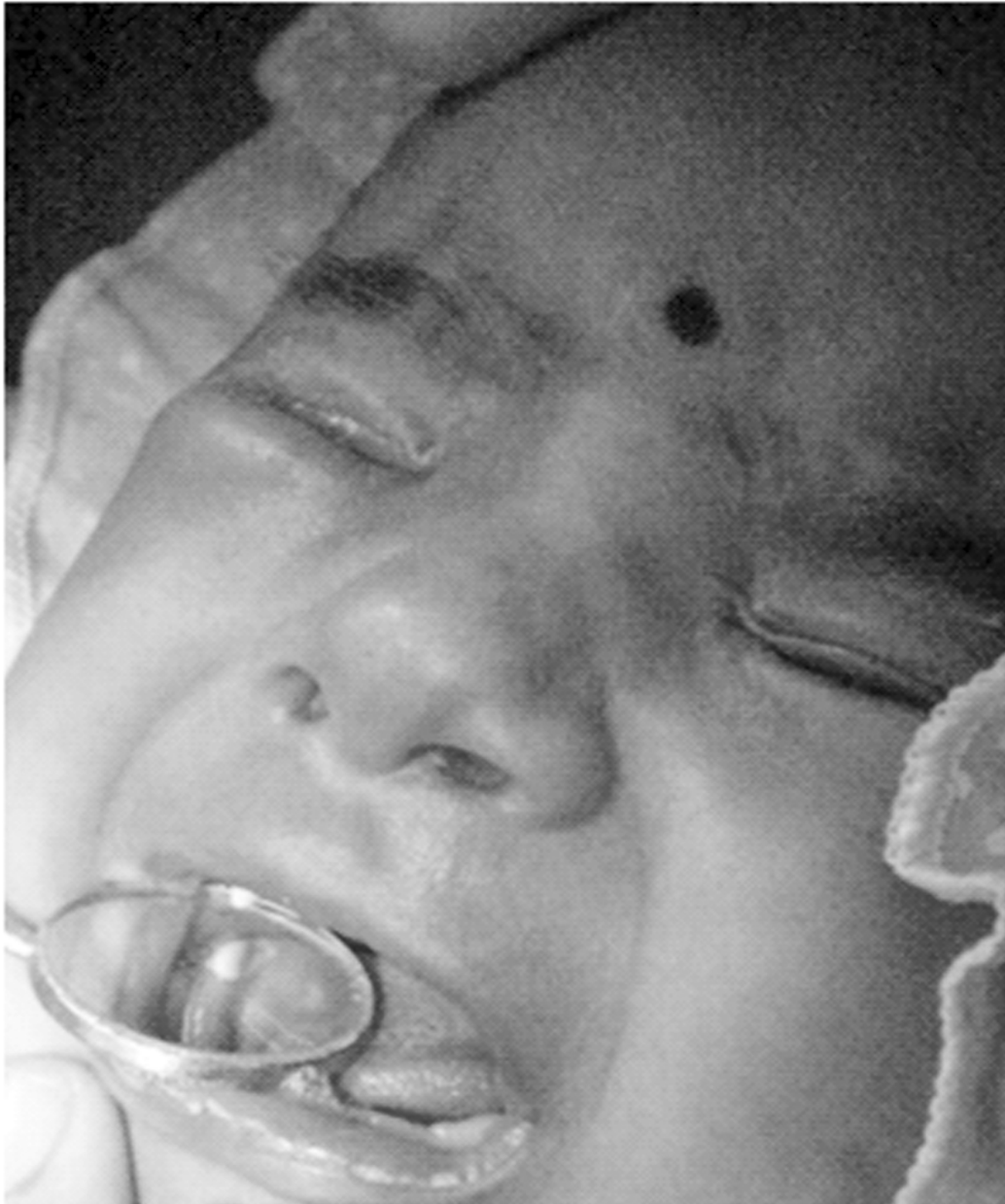On intraoral examination there was a soft whitish yellow mass on the right posterior maxillary alveolar ridge which was associated with purulent discharge. The adjacent palatal mucosa showed erythema and diffuse swelling. (Figure 2)

On palpation, with application of minimum pressure, a thick purulent plug loosened out from the mass followed by more purulent discharge (Figure 3). This purulent plug and discharge was sent for histopathological examination. Histo-pathologically lesion

showed predominantly acute inflammatory cells admixed with chronic inflammatory cells in a minimum oedematous stroma. A thick fibrinopurulent membrane with extensive areas of necrosis was also evident. (Figure 4)

Treatment protocol included thorough drainage of abscess and IV Ceftriaxone + Tazobactam (Ceftriaxone was calculated at 50mg / body weight / day) which resulted in complete healing of the wound by the fifth day. (Figure 5)

Figure 1: Dacryocystitis with cellulites seen on the medial aspect of right eye

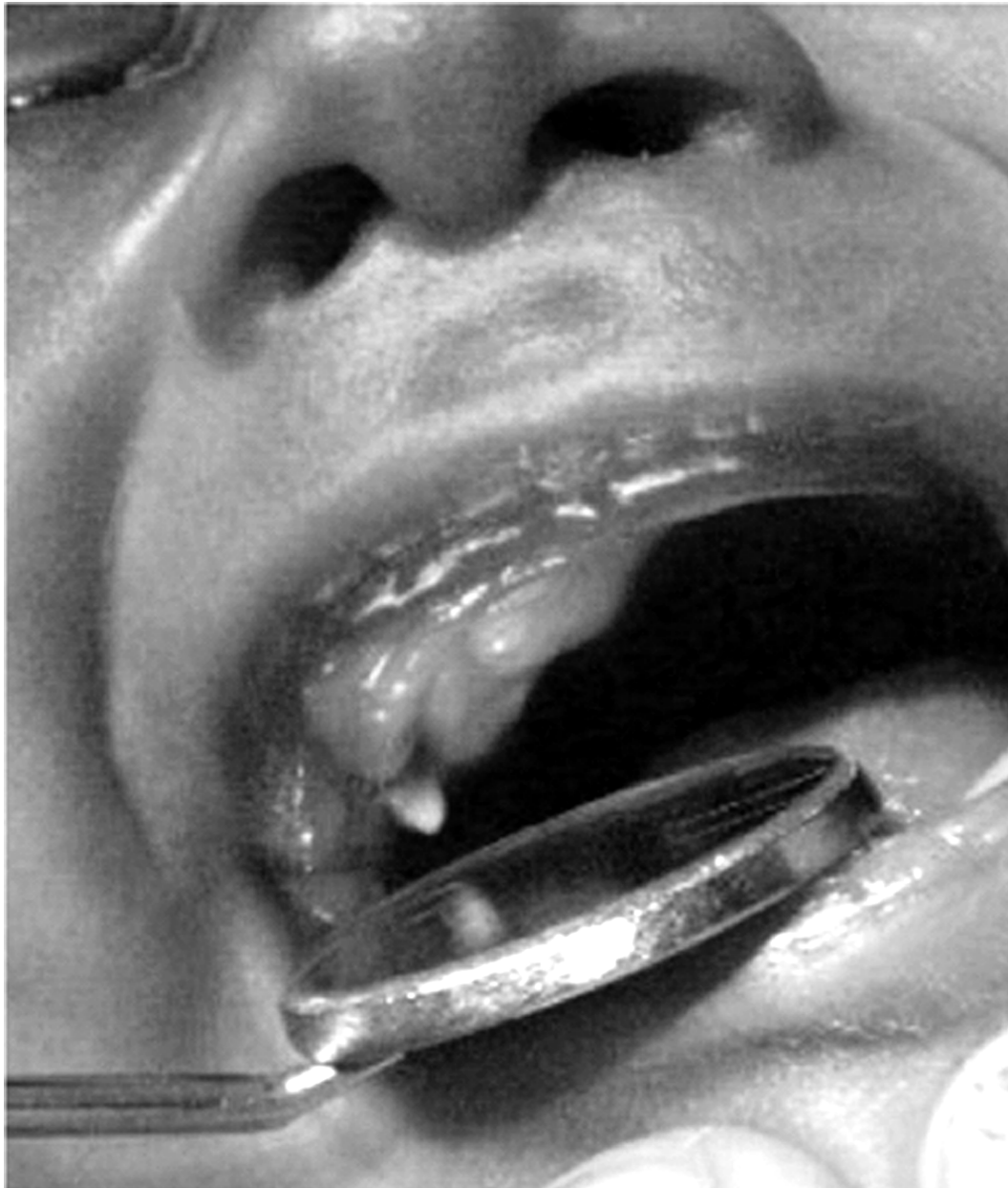

DISCUSSION

Child development from conception through the first years of life is marked by many changes. The clinical features in the infected neonate are frequently vague and may resemble those of other common diseases. The expectations about the eruption of the first teeth are great and even greater when the

teeth appear early in the oral cavity.⁴In the present case, parents reported with a complaint of tooth in the oral cavity. A baby with neonatal tooth also presents with poor feeding and crying during feeding as in this case and 85% of these teeth are mandibular incisors⁵ unlike this case where it appeared to be in the maxillary posterior region. Natal teeth are those that are present at the time of


Figure 2: Whitish yellow mass seen on the right posterior region of maxillary alveolar ridge



birth and neonatal teeth are that erupt during the first 30 days of life⁵

Though it appeared like a tooth on visual examination, it was found to be a yellowish

Figure 3: Thick plug loosed out from the mass



white soft mass on palpation which ruled out the presence of neonatal tooth. Thorough search in the Medline journals and internet source did not give us any report of such case in the past.

This case also presented with swelling of the eye on its medial aspect which was diagnosed as lacrimal sac or duct infection called as Dacryocystitis. Although tear duct infections can occur at any age, they are most common in infants.⁶ In the paediatric population it may

present in either acute or chronic forms.⁷ Findings like pain, redness and swelling of the lower eyelid at the inner corner of the eye, fever, pus or discharge from the eye pointed towards acute Dacryocystitis with cellulites.⁶ Travia in 1967 reported that acute dacryocystitis is accompanied by the poor health of the infant.⁸

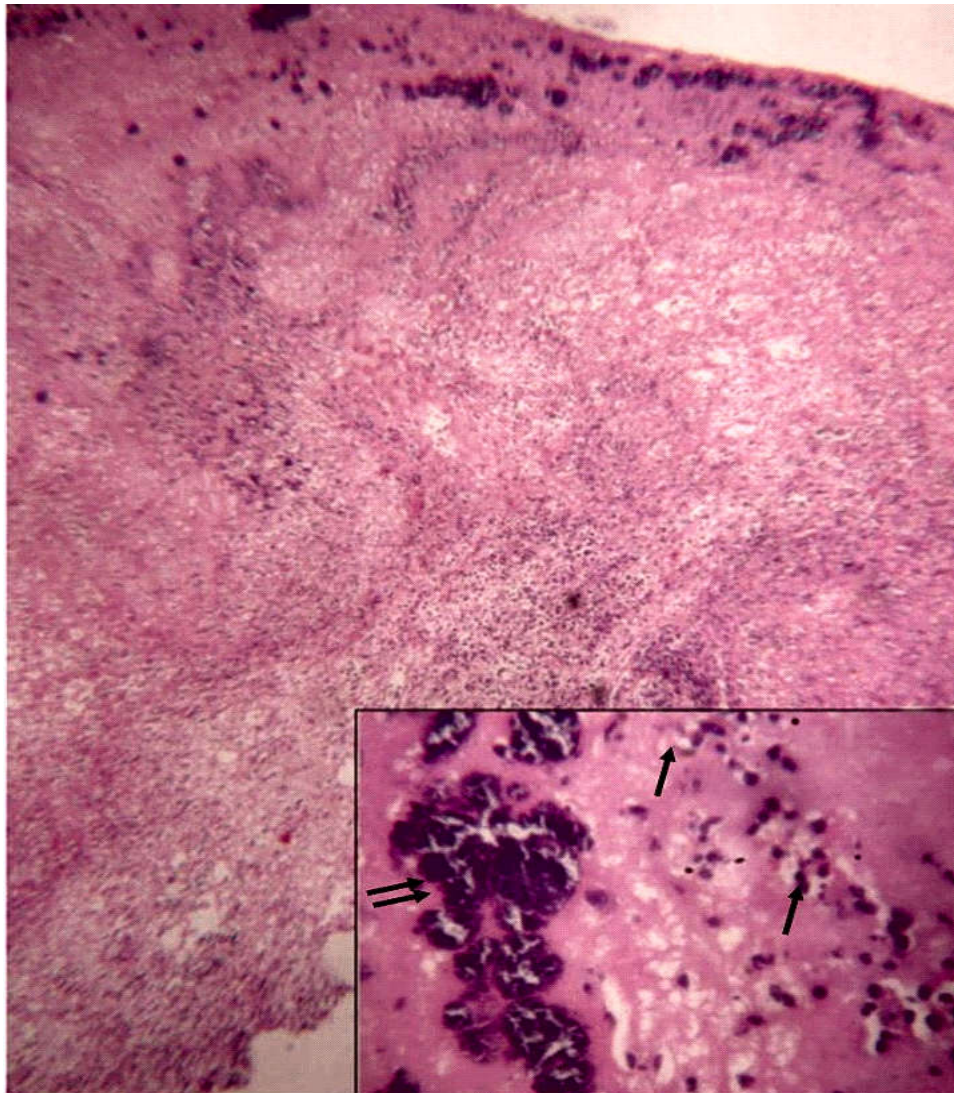
Post delivery, the neonate may acquire infection from the person handling the baby, contaminated air, milk or instrument used for

Figure 4: Histopathological feature showing thick fibrino purulent membrane with extensive area of necrosis and abundant inflammatory cell infiltrate.(10X magnification)

Inset picture (100X)showing :

(Single arrow) : Acute and chronic inflammatory cell

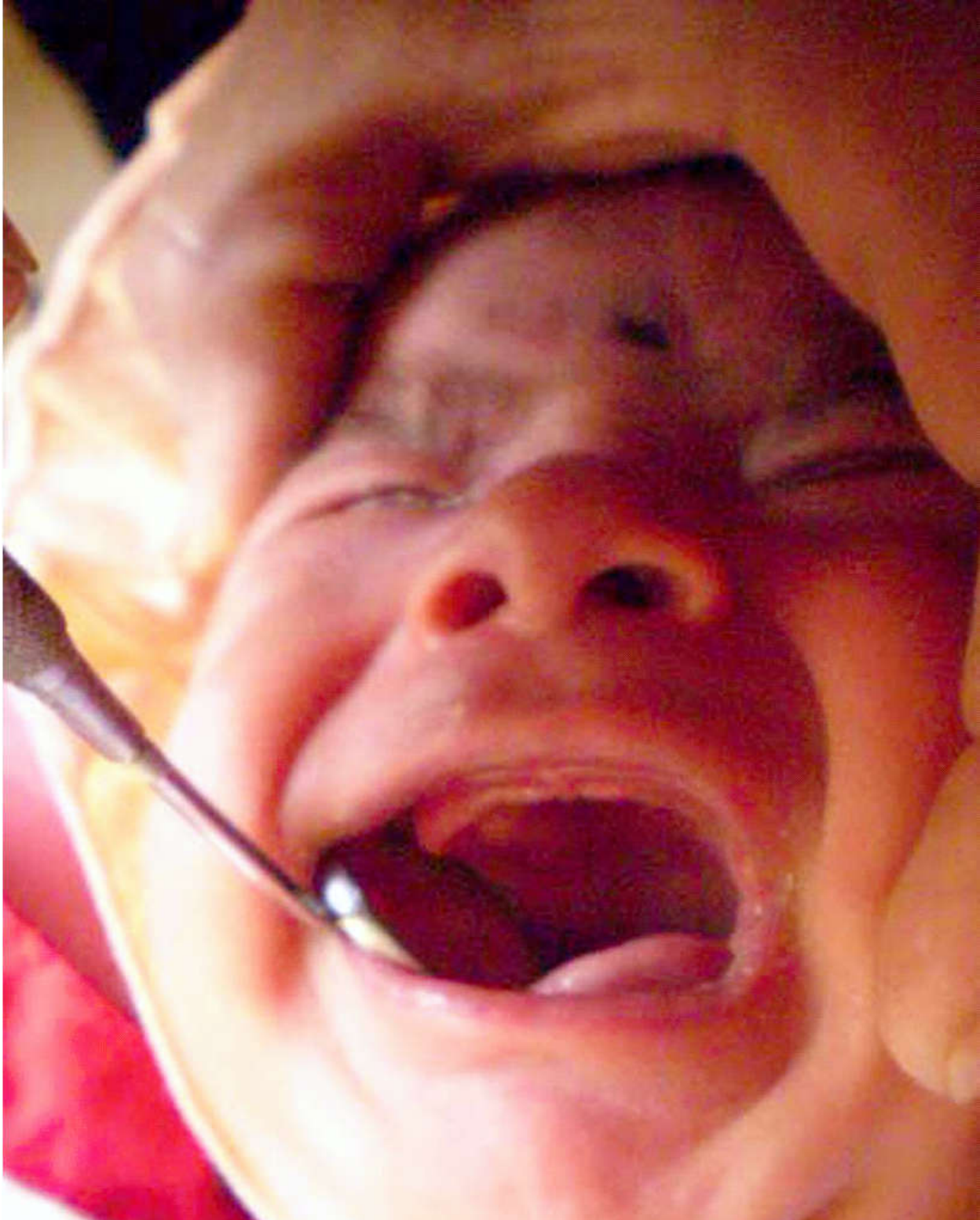
(Double arrow) : Area of necrosis



general care and improper handling and negligence of the care taker. The guidelines and recommendation of infant oral health care

includes cleaning of gum pads using a soft cloth rolled over the finger.⁹

Figure 5: Fifth day of follow up showing complete healing of wound



Mode of transmission in this case could be contact by hands, with spread of infection from eye to the oral cavity due to abrasion caused while cleaning gum pads. Spread from a contiguous source of infection i.e. by adjacent infections with common sites being Maxilla, Mandible, Skull and Hands. Poor hygiene, chronic sinusitis, eye infections are recognized causes of infections¹⁰ Thus it is important to follow good hygiene like clipping the nails, washing the hands while taking infant health care. Other contributing factor could be decreased immunity because of the prematurity.¹¹ The risk of contracting intra and post partum infection is inversely proportional to gestational age. Neonates are immunologically immature with decreased nucleocyte and monocyte functions. Premature infants have decreased intrinsic antibody production and reduced complement activity¹²

The oral lesions that can be present in newborn periods include natal and neonatal teeth, clefts, dental lamina cyst, epstein pearls, bohn nodules, alveolar lymphangioma, Tumors (congenital epulis).³ Epstein pearls are cystic keratin filled nodules found along the mid palatine raphe, probably derived from entrapped epithelial remnants along the line of fusion. Bohn's nodules are also keratin filled cysts but scattered over the palate, most numerous along the junction of hard and soft palate and apparently derived from palatal salivary gland structures. Dental lamina cyst are found on the alveolar ridge of new born or very young infants which represent cyst originating from remnant of the dental lamina. They appear as small, isolated or multiple whitish papule.¹³

The congenital epulis is an oral mass that presents at birth in neonates. Congenital epulis, also known as granular cell tumour of the gingiva, congenital granular cell myoblastoma, or Newmann's tumour. It occurs on the gingiva of the anterior alveolar ridge of the jaws. The tumour presents in the alveolar mucosa as a smooth-surfaced sessile or pedunculated mass with a normal to reddish colour. Its size varies from several

millimetres to a few centimetres in diameter, and it may interfere with respiration or feeding. They are seen 3 times more frequently in the maxillary alveolus than in the mandibular alveolus and the female to male ratio is 10:1.¹⁴

Bohn's nodule, epstein pearl, dental lamina cyst, congenital epulis were excluded out based on the history, site and appearance of mass.

CONCLUSIONS

This case is unusual and significant because what appeared to be neonatal tooth was an inflammatory abscess. Any delay in treatment could have led to septicemia which is fatal. Hence it is of prime importance to follow proper treatment protocol at the right time in order to avoid any emergencies.

REFERENCES

1. Lindia J. Willies-Jacobo et al . Pyogenic Granuloma Presenting as a Congenital Epulis. Arch Pediatr Adolesc Med. 2000;154:603-605.
2. Dilip George et al . Oral Findings in Newborn Children in and around Mangalore, Karnataka State, India. Med Princ Pract 2008;17:385-389.
3. A Mohammadzadeh . N Mokhtari . Oral Lesions at Birth. Otorhinolaryngology 2005;17(41): 3-7
4. Cunha R F et al . Natal and neonatal teeth : review of literature . Pediatric Dent 2001;23(2): 158-162.
5. Anegundi R T et al . Natal and neonatal teeth: report of four cases . J Indian Soc Pedo Prev Dent 2002;20(3):86-92
6. Handbook of Ocular Disease Management, online. Dacryocystitis. <http://www.revoptom.com/handbook/sect1j.htm> April 9, 2001
7. Campolattaro B. N. Spectrum of pediatric dacryocystitis : Medical and surgical management of 54 cases. Journal of pediatric ophthalmology and strabismus; 1997: 34(3) 143-153 .
8. Sen D K . Bilateral acute lacrimal sac abscess in a newborn infant. Indian Journal of Ophthalmology 1984;32(1) 25-27.
9. Shobha Tandon . Text book of Pedodontics. 2nd edition. Paras publication .
10. Joachin Brossmann, David J. Sartoris and Donald L.R : Osseous and Soft tissue infection of Extraspinal sites. In Magnetic resonance imaging. Third Edition.
11. Petrova A et al . Gestational Age Related Maternal-Fetal-Neonatal Humoral Immunity . The Journal of

- Applied Research 2004;4(1):44-49.
12. Edelmann CM, Ogwo JE, Fine BP. The prevalence of bacteremia in full term and Premature Newborn infants. *J. Pediatr* 1973;82:125.
 13. Kumar A et al . Dental lamina cyst of newborn: A 2008 ;175-76.
 14. McGuire T P et al. Congenital Epulis: A Surprise in the Neonate. *J Can Dent Assoc* 2006; 72(8):747-50.
-