

## Mucoepidermoid Carcinoma of Minor Salivary Gland

*Pramod R.C.\**, *Suresh K.V.\*\**, *Mohan Kumar K.P.\*\*\**, *Eby Varghese\*\*\*\**, *Renu Sarah Samson\*\*\*\**

**Author's Affiliation:** \*Senior Lecturer, \*\*\*Reader, Department of Oral Pathology and Microbiology, College of Dental Sciences, Davangere. \*\*Assistant Professor, Dept of Oral Medicine and Radiology, SEGI University, Kuala Lumpur, Malaysia. \*\*\*\*Faculty of Dentistry, Melaka Manipal Medical College, Jalan Batu Hampar, Bkit Baru, Melaka 75150.

**Corresponding Author:** Pramod R.C., Senior Lecturer, Department of Oral Pathology and Microbiology, College of Dental Sciences, Davangere, Karnataka 577004.  
E-mail: [pramodrc@gmail.com](mailto:pramodrc@gmail.com)

### Abstract

Mucoepidermoid carcinomas (MEC) are malignant epithelial neoplasms that usually originate in the salivary glands. MEC mainly occurs in the parotid gland. MEC of minor salivary gland origin in children and adolescents have rarely been reported. It shows a variety of biological behaviors and variable natural history. Here we are reporting a case of MEC in a young male adolescent in the region of palate.

**Keywords:** Intermediate Cells; Mucous Cells; Palate; Salivary Gland.

### Introduction

Mucoepidermoid carcinoma (MEC) is one of the most common salivary gland malignancies [1]. MEC mainly occurs in the parotid gland, along with minor glands being the second common site, particularly in palate [2]. Other sites of presentation have been on the retro molar area, floor of mouth, buccal mucosa, lips and tongue [3]. MEC appears as asymptomatic swellings in minor salivary glands. As its name implies, MEC is composed of a mixture of cells, including mucus, epidermoid or squamous and intermediate types [2]. In this case report, we are describing a low-grade MEC in the region of palate in a 30-year-old male.

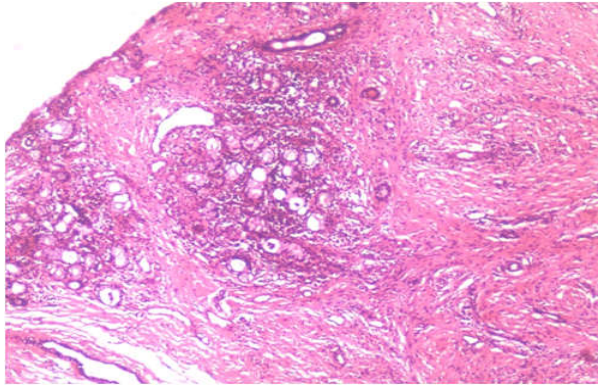
### Case Report

A 30 years old male patient reported with a

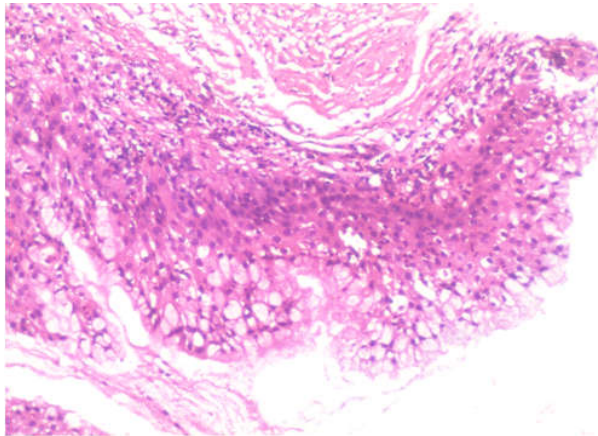
swelling in the left side of the roof of mouth for the past one year. It was started spontaneously as a small swelling which then gradually increased to the present size. It was associated with pain for the past one week. Patient gives history of maxillary left 2<sup>nd</sup> molar extraction one and half year back. Family history was not significant. Patient was in good physical condition. Extra-oral examination was unremarkable. On intraoral examination, [Figure 1] a circular shaped swelling measuring about 1.0 cm × 1.0 × 0.5 cm seen on the right part of the palate slightly left to the midline. No secondary changes were seen. On palpation of the lesion, all inspectory findings were confirmed, swelling was non-tender, soft to firm in consistency with regular smooth borders. Based on history and presentation residual cyst and pleomorphic adenoma were considered as differential diagnosis. Incisional biopsy performed under local anesthesia. Histopathology of the specimen reveals tumor composed of squamous cells, intermediate cells and mucin-secreting cells (Grade I) [Figure 2, 3 and 4]. After histopathological diagnosis, surgical excision of the whole tumor was done under local anesthesia. The patient is under follow up since 1 year with no recurrence.

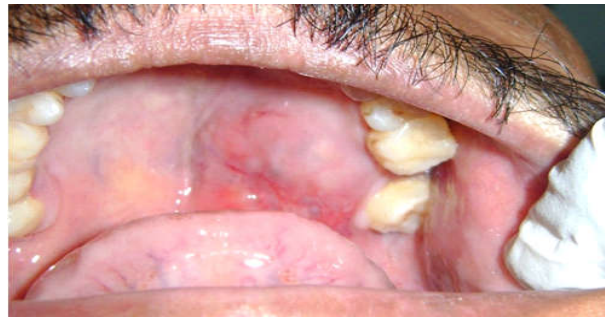

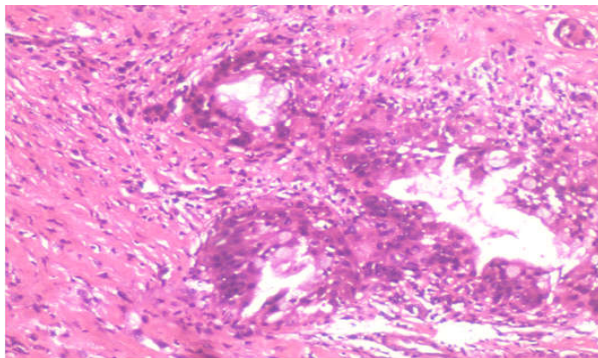
Fig. 1: Showing swelling over the palate



**Fig. 2:** Photomicrograph (10X) showing proliferation of tumor cells



**Fig. 3:** Photomicrograph (40X) showing proliferation mucous cells and intermediate cells



**Fig. 4:** Photomicrograph (40X) showing proliferation intermediate cells and minimal amount of squamous or epidermoid cells

### Discussion

MEC is the most common malignant salivary gland neoplasm in adolescence and is rarely found in children under the age of 10 years [2]. MEC is believed to arise from the reserve cells of excretory ducts [3]. Of all salivary gland neoplasms, minor salivary gland tumors account for 10–15% with a common complaint of painless swelling, with symptoms being present for more than 12 months [4]. Paraesthesia, pain and

difficulty in swallowing are noted frequently when major salivary glands and tongue are involved. 75% cases of minor salivary gland tumors originate in the palate, buccal mucosa and upper lip with palate being the most common site (55%) and more than 60% of these are malignant. The common age group for the occurrence of MEC is around 43 years. The overall female predilection is more. In this case the site of occurrence is in consistent with the literature and female predilection is not consistent with the literature [1,3,5]. Volkmann first described MEC in 1895 and Stewart further elaborated it as mucoepidermoid tumor in 1945. The credit for naming it as MEC goes to Foot and Frazell (1953) [6]. As its name suggests, it is composed of a mixture of epidermoid cells, mucous cells and poorly differentiated intermediate cells [4]. The differential diagnosis for MEC is generally to distinguish it from other salivary gland tumors like adenosquamous carcinoma, polymorphous low-grade carcinoma and squamous cell carcinoma [6]. Metastasis and survival rate are related to the histological grade and stage [4]. The treatment for MEC in minor salivary glands is primarily surgical. A wide excision with removal of underlying bone if involved is recommended [4]. Prognosis is dependent on grade where low grade tumours have 90 - 98% survival and a low local recurrence rate compared to 30-54% survival and a very high local recurrence rate for high grade tumours [5-6].

### Conclusion

Swellings in the palatal region resemble dental abscess and cyst, which can lead wrong diagnosis as benign or inflammatory lesion which causes local destruction, so early diagnosis and treatment of the lesion leads to better outcome and good prognosis. Hence, every clinician should be aware of the various palatal swellings with their clinical course and appearance of the lesions for better management and prognosis.

### References

1. Kolude B, Lawoyin JO, Akang EE. Mucoepidermoid carcinoma of the oral cavity. *J Natl Med Assoc* 2001; 93:178-84.
2. Ritwik P, Corde l l KG, Brannon RB. Minor salivary gland mucoepidermoid carcinoma in children and adolescents. a case series and review of the literature. *J Med Case Rep* 2012; 6:182
3. Rahbar R, Grimmer JF, Vargas SO, Robson CD, Mack JW, PerezAtayde AR, et al. Mucoepidermoid

- carcinoma of the parotid gland in children A 10-year experience. Arch Otolaryngol Head Neck Surg 2006; 132:375-80.
4. Ozawa H, Tomita T, Sakamoto K, Tagawa T, Fujii R, Kanzaki S et al. Mucoepidermoid carcinoma of the head and neck: clinical analysis of 43 patients. Jpn J ClinOncol. 2008; 38(6):414.
  5. Savelli SL, Klopfenstein KJ, Termuhlen AM. Mucoepidermoid carcinoma of the parotid gland as a second malignant neoplasm. Pediatr Blood Cancer 2005; 45:997-1000.
  6. Brandwein MS, Ivanov K, Wallace DI, Hille JJ, Wang B, Fahmy A. et al. Mucoepidermoid carcinoma: a clinicopathologic study of 80 patients with special reference to histological grading. Am J SurgPathol. 2001; 25(7):835-45.
- 

### Special Note!

Please note that our all Customers, Advertisers, Authors, Editorial Board Members and Editor-in-chief are advised to pay any type of charges against Article Processing, Editorial Board Membership Fees, Postage & Handling Charges of author copy, Purchase of Subscription, Single issue Purchase and Advertisement in any Journal directly to Red Flower Publication Pvt. Ltd. Nobody is authorized to collect the payment on behalf of Red Flower Publication Pvt. Ltd. and company is not responsible of respective services ordered for.