

Gastrointestinal stromal tumors (GIST): A Pathologist's Viewpoint

Jain Ila

Gastrointestinal stromal tumors (GISTs) are rare mesenchymal tumors that arise from the intestinal cells of Cajal, the gut pacemaker cells^{1,2}. They are the most common sarcoma of the gastrointestinal tract, representing 0.2% of all GI tumors. The usual presentation is as an abdominal lump or upper GI bleeding³. On rare occasions, however they can also manifest as a part of a tumor syndrome, such as CARNEY'S triad (gastric GIST, paraganglioma and pulmonary chondroma).

Based on their phenotypic features, they can be roughly divided into three major categories

Tumors showing differentiation towards smooth muscle cells which usually express Smooth Muscle Actin (SMA), desmin, calponin, myosin etc.

Tumors showing differentiation towards neural elements which show neural like features such as long cytoplasmic processes, dense core neurosecretory granules etc. These tumors have been called as Gastrointestinal Autonomic Nerve Tumours (GANTS) or Plexysarcomas. They have a greater malignant

potential as compared to GISTs and these tumors exhibit non specificity in immunohistochemical markers like NSE and S-100.

Tumors showing dual differentiation both towards smooth muscle and neural elements.

Macroscopic findings

They may be single or multiple and vary in size from tiny intramural lesions to bulky tumor masses. Most neoplasms protrude from the outer surface as exophytic subserosal lesions. They are usually well circumscribed, nodular or bosselated masses and lack a true capsule. The cut surface is gray to pink in color with a rubbery consistency. It lacks the whirling smooth muscle pattern of leiomyomas.

Microscopy

The two basic histopathological types of GIST are the spindle and epithelioid varieties.

Spindle cell GIST

They are composed of interlacing bundles or whorls of uniform spindle shaped cells with ovoid nuclei and fibrillary eosinophilic cytoplasm which may contain a clear paranuclear vacuolae. Skeinoid fibres, which are small, globular or curvilinear eosinophilic aggregates of filamentous material may be scattered among the tumor cell

Epithelioid GIST

They occur more commonly in antrum and consist of round vacuolated or clear cells arranged in cohesive sheets or nests which impart an epithelioid pattern. Nuclei are round to ovoid, with finely dispersed chromatin and small nucleoli.

**MBBS, DNB Scholar, Senior Research Fellow, Institute of Pathology (ICMR), Safdarjung Hospital Campus, New Delhi 110029

Correspondance: Dr. Ila Jain, Senior Research Fellow, Institute of Pathology, Indian Council of Medical Research, Safdarjung Hospital Campus, New Delhi 110029, Telephone number: 011-26198402-6 Ext 435, Fax number: 011-26198401 Email: jain_ila@rediffmail.com

Immuno-histochemistry

Most important advance in the diagnosis of GIST is the discovery of CD-117(c-KIT), a tyrosine kinase receptor expressed by the interstitial cells of Cajal. More than 95 % of the tumors are positive for CD - 117 and the diagnosis of GIST should be questioned when the tumor is CD- 117 negative [4]. Staining is usually strong and widespread and may be distributed in the cytoplasm, localized to a

perinuclear dot, or membranous. Since CD 117 is a tyrosine kinase receptor, it explains the fact that some of these tumors are sensitive to the action of Imatinib mesylate (a tyrosine kinase inhibitor).

A small number of GISTs may have mutations in another gene called as the platelet derived growth factor receptor alpha (PDGFRA). Most gastric GISTs also express CD-34. Few might show positivity with smooth muscle actin, desmin or S-100.

	SIZE(cm)	MITOTIC COUNT(PER 50 HPF)
Very Low Risk	<2	<5
Low Risk	2-5	=5
Intermediate Risk	=5	6-10
	5-10	=5
High Risk	>5	>5
	>10	Any mitotic rate
	Any size	>10

Predicting behavior

The behavior of GISTs can be predicted by the estimation of the size of tumor and the mitotic rate⁵. The various guidelines given by Fletcher CDM are:

References

1. Mazur MT, Clark HB. Gastric stromal tumors: Reappraisal of histogenesis. *Am J Surg Path* 1983; 7: 507-519.
2. Nilson B, Bumming P, Meis- Kindblom JM, et al. Gastrointestinal stromal tumors: The

incidence, prevalence, clinical course, and prognostication in the pre-imatinib mesylate era. *Cancer* 2005; 103: 821-829.

3. Connolly EM, Gaffney E, Reynolds JV: Gastrointestinal stromal tumors. *Br J Surg* 2003; 90: 1178.
4. Rubin BP, Singer S, Tsao C, et al. KIT activation is a ubiquitous feature of gastrointestinal stromal tumors. *Cancer Res* 2001; 61: 8118- 8121.
5. Fletcher CD, Berman JJ, Coreless C, et al. Diagnosis of gastrointestinal stromal tumors: A consensus approach. *Human Path* 2002; 33: 459-465.

Figure 1: High power view of a gastric GIST showing spindle shaped cells arranged in a palisading pattern

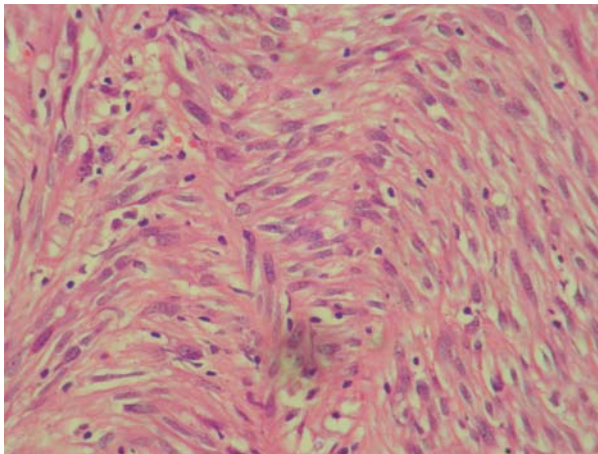


Figure 2: Photomicrograph showing CD-117 positivity

