

Comparison of Serratus Anterior Plane Block between 0.125% Bupivacaine 20ml and 0.2% Ropivacaine 20ml for Postoperative Analgesia in Adult Unilateral Breast Surgeries

Chaitana NH¹, C Dhanasekaran², Harish Prabhakaran³, Ashwini Lonimath⁴

Author's Affiliation: ¹Post Graduate, ²Professor, ³Lecturer, Anesthesiology, ⁴Senior Resident, Department of Community Medicine, Rajah Muthiah Medical College and Hospital, Annamalai University, Tamil Nadu 608002, India.

Abstract

Background: In recent years, interfascial plane blocks are used to reduce pain and opioid consumption for multimodal analgesia strategies. Serratus Anterior Plane (SAP) block is widely used clinical practice, in which local anesthetics are injected into the fascial plane superficial or deep to the serratus anterior muscle (SAM). This will block the lateral cutaneous branches of the intercostal nerves, this effectively relieving postoperative pain for procedures such as breast surgery, thoracoscopic surgery, rib fractures, and minimally invasive heart surgery.

Aim & Objective of the Study: The study aims to compare Serratus Anterior Plane Block between 0.125% Bupivacaine 20ml and 0.2% Ropivacaine 20ml for the duration of postoperative Analgesia.

Methods: The clinical study was conducted in the Department of Anaesthesiology at Rajah Muthiah Medical College and hospital, Annamalai University from December 2019 to September 2021. The study includes 40 adults patients coming for elective adult breast surgeries. Patients were assigned by random numbers into one of the two treatment groups: Serratus Anterior Plane block with 20ml Bupivacaine 0.125% (group B) and 20ml Ropivacaine 0.2% (Group R). The parameters monitored and recorded are heart rate, blood pressure, VAS score, and side effects. The results were subjected to statistical analysis.

Results: Heart rate variation between the groups, (group B and group R) at regular intervals from 0 mins to 24 hours is not statistically significant ($p > 0.05$). Systolic Blood Pressure variation between the groups (group B and group R) at regular intervals from 12 to 24 hours, is statistically significant ($p < 0.05$). Diastolic Blood Pressure variation between the groups, group B and group R, at regular intervals from 0 to 24 hours, is not statistically significant ($p > 0.05$). Duration of postoperative analgesia was prolonged in Group R 16.7 ± 3.8 hrs when compared with Group B 9 ± 1.7 hrs. The p value was based on independent sample t test which gives a value of < 0.05 . Thus the difference between the two groups is statistically highly significant.

Conclusion: In this study it is concluded that Ropivacaine (0.2%) provide better postoperative pain relief than Bupivacaine (0.125%) in Serratus Anterior Plane Block for unilateral Breast Surgeries.

Keywords: Serratus Anterior Plane Block; Ropivacaine; Bupivacaine.

How to cite this article:

Chaitana NH, C Dhanasekaran, Harish Prabhakaran, Ashwini Lonimath/Comparison of Serratus Anterior Plane Block between 0.125% Bupivacaine 20ml and 0.2% Ropivacaine 20ml for Postoperative Analgesia in Adult Unilateral Breast Surgeries/Indian J Anesth Analg. 2022;9(1):9-13.

Corresponding Author: C Dhanasekaran, Professor, Rajah Muthiah Medical College and Hospital, Annamalai University, Tamil Nadu 608002, India.

E-mail: drdhanss@gmail.com

Received on: 01.12.2021, **Accepted on:** 03.12.2021



This work is licensed under a Creative Commons Attribution-NonCommercial-ShareAlike 4.0.

Introduction

More than 80% patients who undergo surgical procedures experience acute postoperative pain and evidence suggest that less than half of patients who undergo surgery report adequate postoperative pain relief. Inadequately controlled pain negatively affects quality of life, function and functional recovery the risk of postsurgical complication and the risk of persistent postsurgical pain and delayed recovery time. Prolonged duration of opioid use and higher health care cost, in addition the presence and intensity of acute pain during or after surgery is predictive of the development of chronic pain.¹

Postoperative pain relief reduces surgical stress responses such as endocrine, metabolic and inflammatory. Only regional technique may lead to substantial reduction in surgical stress response.² Intense nociceptive somatic and visceral post surgical pain in the last 10 years has been considered the most important development of endocrine and neurohumoral disorders in the immediate postsurgical period. It is characterized by increase catabolism, increased secretion of stress hormones, increased burdening of the CVS system, lung function disorders, occurrence of hypercoagulability, fibrinolysis decline immunological suppression, paralytic ileus and post surgical nausea and vomiting.^{3,4,5}

Materials and Methods

The clinical study was conducted in the department of anesthesiology at Rajah Muthiah Medical College and hospital, Annamalai University from December 2019 to September 2021. The study was approved by Hospital ethical committee. Written informed consent was obtained from all the patients. The study includes 40 adults patients coming for elective adult breast surgeries.

Inclusion Criteria

Age between 18 to 60 years of both sexes. ASA I and II. Patients posted for Gynecomastia, Carcinoma breast, Fibroadenomas, Phyllodes tumor surgeries.

Exclusion Criteria

Patient refusal, Patients less than 18 years, Allergic to Local anesthetics, Local infection. In all patients selected for the study a detailed general physical examination including airway assessment, spine and systemic examination was done to confirm the previously mentioned inclusion and Exclusion criteria.

Patients were advised to remain nil per oral after midnight. An IV access was secured using 18G IV cannula and RL was allowed to flow. Emergency drugs and equipments were kept ready to manage failure or complications. Basal vital parameter like PR,BP ,ECG, respiration and oxygen saturation were recorded. Surgery was done under standard General Anesthesia. Before extubation patient was positioned in supine position and under all aseptic precaution the chest was painted with povidone iodine solution. By palpating 4th and 5th rib at mid axillary line the

Serratus Anterior Plane identified. Drug loaded by separate anaesthesiologist will be administered in ipsilateral Serratus Anterior Plane. Postoperative monitoring will be done by a anaesthesiologist who is not involved in the study. Once Visual Analogue Scale reached 4, injection Diclofenac 75 mg im will be administered. At the end of the study the numbers were decoded and subjected to the suitable statistical analysis.

Statistical Analysis

All statistical analyses were carried out using SPSS statistics program version 22.0 (IBM Corporation, Armonk, NY, USA). Data were assessed for normal distribution by the Shapiro-Wilk test. Quantitative data are expressed as mean (standard deviation) or median (interquartile range), and were compared by 1-way analyses of variance or nonparametric test. Qualitative data are expressed as number (proportion), and were compared by chi-square test. Multiple comparison was tested by Mann-Whitney U tests. Statistical significant was considered as $P < 0.05$. To reduce type I error, statistical significant in post hoc multiple comparisons was correct as $P < 0.017$.

Results

Graph 1: Age Distribution

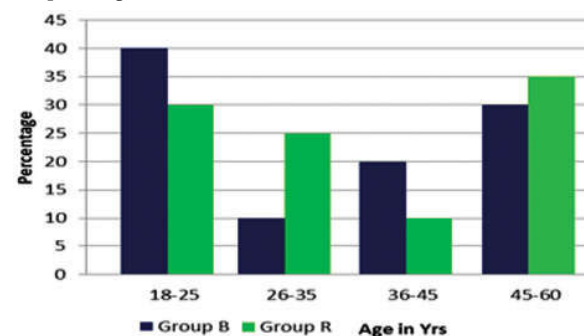


Table 1: Shows The age distribution between the two groups were depicted in the above table. More

number of patients belonged to the age group of 26 to 35 years. The p-value between the two groups was >0.05 and hence both the groups were comparable.

Graph 2: Type of Surgery.

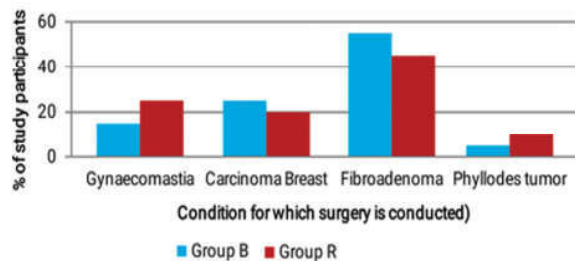
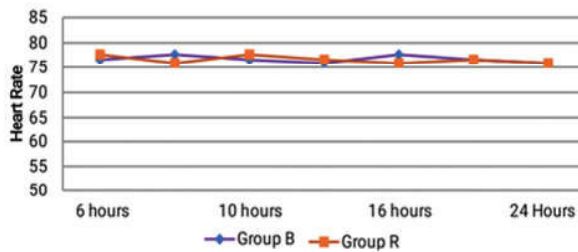


Table 2: Shows the type of surgery between the two groups was depicted in the above table. P value was based on Fisher exact probability test and the value is <0.05 and hence both the groups are comparable.

Graph 3: Mean Heart Rate



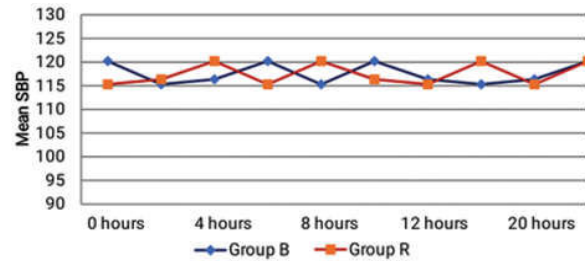
As shown in Graph 3 Heart rate variation between the groups, (group B and group R) at regular intervals from 0 mins to 24 hours is not statistically significant ($p>0.05$).

As shown in Graph 4: Systolic Blood Pressure variation between the groups, group B and group R, at regular intervals from 12 to 24 hours, is statistically significant ($p<0.05$).

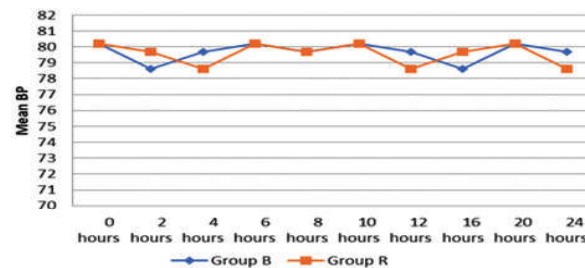
As shown in Graph 5: Diastolic Blood Pressure variation between the groups, group B and

group R, at regular intervals from 0 to 24 hours, is not statistically significant ($p>0.05$).

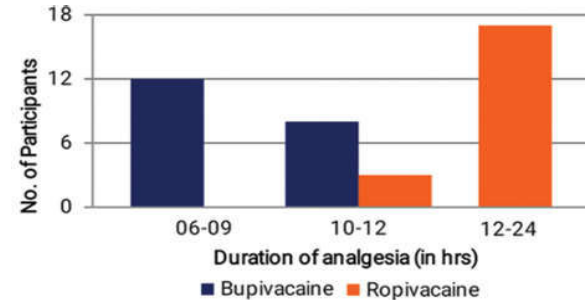
Graph 4: Mean Systolic Blood Pressure.



Graph 5: Mean Diastolic Blood Pressure.

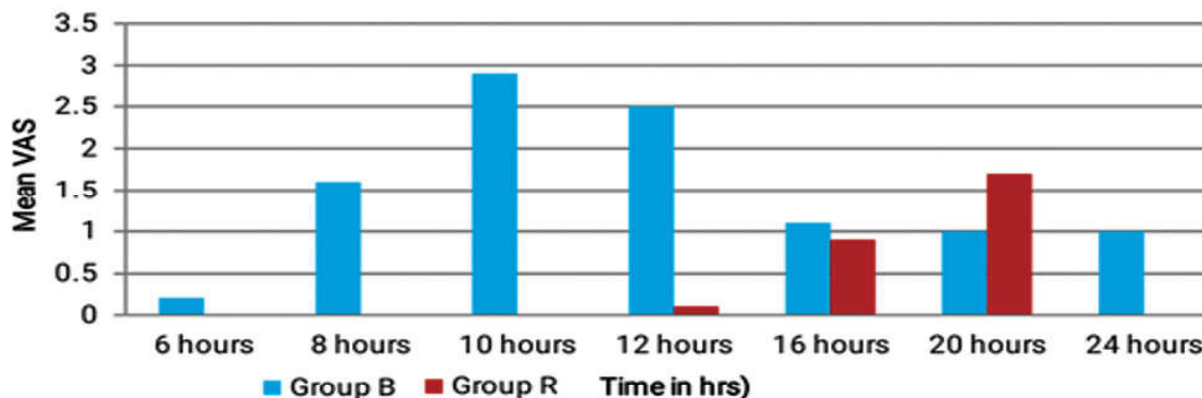


Graph 6: Duration of Analgesia.



Graph 6: The mean Duration of Analgesia for Group B was 9.1 ± 1.7 hours and for Group R was 16.7 ± 3.8 hours. Duration of post operative analgesia was prolonged in Group R when compared with Group B. The p value was based on independent sample t test which gives a value

Graph 7: Vas Score



of <0.05 . Thus the difference between the two groups is statistically highly significant.

Graph 7: VAS score between the two groups group B and R at regular intervals from 60mins to 24 hours is depicted in above table and is statistically significant P value <0.05 .

Discussion

Although general Anesthesia continues to be used for most of the surgical procedures, regional anesthesia has been increasing in popularity in recent years. This is mainly because of the fact that the regional anesthesia techniques can be utilized for analgesia not only during the intraoperative period but during the postoperative period as well.⁶ In our study, Bupivacaine and Ropivacaine was used as local anaesthetic.⁸ Our study was a randomized, prospective, double-blinded and controlled study.

Dirks J et.al⁹, Did a comparative study on volunteers with informed consent on 4 patients. Two different blocks were performed on each volunteer on each side with 0.4 ml/kg levobupivacaine 0.125% mixed with 0.1mmol/kg gadolinium. the first block was superficial to the serratus anterior muscle and the other was deep underneath the muscle on the contralateral side to compare the intercostal nerve and the long thoracic nerve. The study concluded that The mean duration of paraesthesia was 752 min for the intercostal nerves and 778 min for the motor nerves after injection superficial to serratus anterior. After injection deep underneath the serratus anterior, the mean duration of action was 386 min for the intercostal nerves and 502 min for the motor nerves. The area of sensory loss to pinprick was consistent whether the injection was superficial or deep underneath the muscle. The MRI scan with gadolinium delineated the spread of the injection, and again there was a well-defined band of high-intensity signal with good spread.

Rashwan DAEK et.al¹⁰, treated a 73-year-old woman who underwent left partial mastectomy and axillary node dissection for breast cancer with Serratus Anterior Plane Block with 10 mL of 1% lidocaine; this treatment was repeated 10 times over 6 months at 2 to 4 week intervals and she was simultaneously treated with pharmacological, physical, and cognitive-behavioral therapy.

Fassoulaki A et.al¹¹, performed a study on a 78 year old woman who underwent radical mastectomy and axillary dissection. With informed consent Serratus Anterior Plane Block was done with 25 ml of 0.5% levobupivacaine solution, even PECS 1 block was

performed by infecting in the fascia between minor and major pectoral muscles with 10 ml of 0.375% levobupivacaine and parasternal block with 5 ml of 0.375% levobupivacaine was performed. The study concluded that the association between SPB, PECS 1 block, and Parasternal la injections, ensured good quality and long-lasting analgesia. in the first 24 hours after surgery, the patient did not request opiates.

Fusco P et.al¹², did Serratus Anterior Plane Block on a 63 year old man morbidly obese with multiple rib fractures with epidural needle and catheter with continuous infusion of 0.0625% bupivacaine with 1 µg/mL of fentanyl using an elastomeric pump was started at 7mL/h after 4 hours. An infusion was increased to 12 mL/h the next day since the patient had pain in his left lower chest after the effect of the bolus dosage decreased. Thereafter the patient's static and dynamic VAS pain scores were reduced to 00 and 10-20 respectively and he was able to ambulate and undergo respiratory physiotherapy without pain. The study concluded that Ultrasound-guided serratus anterior plane block is a simple and effective technique for providing pain relief in unilateral Multiple Rib Fractures, especially in obese patients who have obstructive sleep apnea.

Gan TJ¹³, et al. did a prospective randomized pilot study, which involved 50 patients undergoing elective thoracotomy for lung surgery. In Group I patients, an ultrasound (USG)-guided paravertebral catheter was inserted preoperatively with 0.2% Ropivacaine bolus 0.1 ml/kg. In Group II patients, a serratus anterior plane (SAP) catheter was inserted by the surgeon before closure. 0.375% Ropivacaine bolus 0.4 ml/kg was given before extubation. Followed by its continuous infusion for 24 hours. If the numerical rating scale (NRS) was >3 , then patients were given intravenous (i.v.) morphine 3 mg. The study concluded that SAP block with continuous catheter technique seems to be a safe and effective modality for the management of acute postoperative pain after thoracotomy. Duration of effective postoperative analgesia is more in SAP Block.

Conclusion

Administration of Ropivacaine (0.2%) 20ml to the Serratus Anterior Plane Block provide 16.7±3.8 hours and Bupivacaine (0.125%) 20ml in Serratus Anterior Plane Block provide 9.1±1.7 hours. With this study, we conclude Ropivacaine (0.2%) provides prolonged postoperative pain relief than Bupivacaine (0.125%) in Serratus Anterior Plane Block for adult unilateral Breast Surgeries.

Ethical Committee Clearance: Approved

Institution Source of Support: Nil

Conflict of Interest: None

References

1. Apfelbaum JL, Chen C, Mehta SS, Gan TJ: Postoperative pain experience: Results from a national survey suggest postoperative pain continues to be undermanaged. *Anesth Analg* 97:534-540, 2003.
2. Bhan S, Mishra S, Gupta N, Garg R, Vig S, Thulkar S, Kumar R, Bhatnagar S. *Turk J Anaesthesiol Reanim*. 2021 Apr;49(2):124-129.
3. Bhoi D, Pushparajan HK, Talawar P, Kumar A, Baidya DK. Serratus anterior plane block for breast surgery in a morbidly obese patient. *J Clin Anesth*. 2016;33:500-1.
4. Blanco R, Parras T, McDonnell JG, Prats-Galino A. Serratus plane block: a novel ultrasound-guided thoracic wall nerve block. *Anesthesia*. 2013;68:1107-13.
5. Chandrasekharan NV, Dai H, Roos KLT, et al. COX-3, a cyclooxygenase-1 variant inhibited by acetaminophen and another analgesic/antipyretic drugs: cloning, structure, and expression. *Proc Natl Acad Sci U S A* 2002;15:13926-31.
6. Chia YY, Liu K, Wang JJ, et al. Intraoperative high dose fentanyl induces postoperative fentanyl tolerance. *Can J Anaesth* 1999;46:872-7.
7. Chou R, et al Management of postoperative pain: a clinical practice guideline from the American Pain Society, the American Society of Regional Anesthesia and Pain Medicine, and the American Society of Anesthesiologists Committee on Regional Anesthesia, Executive Committee, and Administrative Council J Pain 2016 17 2 131.
8. Comparison of analgesic efficacy of ultrasound-guided thoracic paravertebral block versus surgeon-guided serratus anterior plane block for acute postoperative pain in patients undergoing thoracotomy for lung surgery-A prospective randomized study. Patel A, Kumar V, Garg R, Bhatnagar S, Mishra S, Gupta N, Bharti SJ, Kumar S. *Saudi J Anaesth*. 2020 Oct-Dec;14(4):423-430.
9. Dirks J, Fredensborg BB, Christensen D, et al. A randomized study of the effects of a single dose of gabapentin versus placebo on postoperative pain and morphine consumption after mastectomy. *Anesthesiology* 2002;97:560-4.
10. Rashwan DAEK, Mohammed AR, Kasem Rashwan SA, Abd El Basset AS Efficacy of Serratus Anterior Plane Block Using Bupivacaine/ Magnesium Sulfate Versus Bupivacaine/ Nalbuphine for Mastectomy: A Randomized, Double-Blinded Comparative Study. *Anesth Pain Med*. 2020 Jun 22;10(3).
11. Fassoulaki A, Patris K, Sarantopoulos C, et al. The analgesic effect of gabapentin and mexiletine after breast surgery for cancer. *Anesth Analg* 2002;95:985-91.
12. Fusco P, Scimia P, Marinangeli F, Pozzone T, Petrucci E. *Minerva Anestesiologica*. 2016 Feb;82(2):241-2.
13. Gan TJ, Habib AS, Miller TE, White W, Apfelbaum JL: Incidence, patient satisfaction, and perceptions of post-surgical pain: Results from a US national survey. *Curr Med Res Opin* 30:149-160, 2014.
14. Gee NS, Brown JP, Dissanayake VU, et al. The novel anticonvulsant drug, gabapentin (Neurontin), binds to the alpha2delta subunit of a calcium channel. *J Biol Chem* 1996;271:5768 - 76.
15. Graham GG, Graham RI, Day RO. Comparative analgesia, cardiovascular and renal effects of celecoxib, rofecoxib and acetaminophen (paracetamol). *Curr Pharm Des* 2002;8:1063-75.

