

Modified Limberg Flap for Sacrococcygeal Pilonidal Sinus: A Prospective Institutional Study

Johnrose Austin Jayalal¹, Selwyn J Kumar², Baghavath Pon Kailasm³

Author Affiliation: ¹Professor, ^{2,3}Assistant Professor, Department of Surgery, Kanyakumari Government Medical College, Asaripallam, Kanyakumari, Tamil Nadu 629201, India.

Corresponding Author: Johnrose Austin Jayalal, Professor, Department of Surgery, Kanyakumari Government Medical College, Asaripallam, Kanyakumari, Tamil Nadu 629201, India.

E-mail: lapsurgeon2001@yahoo.co.in

Received on 26.04.2019; **Accepted on** 20.05.2019

How to cite this article:

Johnrose Austin Jayalal, Selwyn J Kumar, Baghavath Pon Kailasm. Modified Limberg Flap for Sacrococcygeal Pilonidal Sinus: A Prospective Institutional Study. Journal of Plastic Surgery and Transplantation. 2020;1(2):49-54.

Abstract

Background: Sacrococcygeal pilonidal sinus is an acquired disease commonly seen in young adults especially males in gluteal cleft and it is known for recurrence and affects the patient's quality of life. Rhomboid excision of sinus with Limberg rotation flap coverage is a well-known surgical modality for this. This prospective study is carried out to determine the effects of the Limberg flap rotation surgery especially for its feasibility in a General surgical unit for the sacrococcygeal pilonidal sinus patients, their compliance, outcomes of the surgery such as wound infection, postoperative pain relief, recurrence rates, and back to routine duration.

Patients and methods: This is a prospective study of 40 Limberg flaps done from 2017 January to 2018 December in general surgical unit by the same surgical team for both primary and recurrent Pilonidal sinuses, and patients who previous incision and drainage had done for the pilonidal abscess. The various demographic, clinical and surgical data are studied and compared to other studies.

Results: There were 34 (85%) male patients and 6 (15%) female patients and all patients successfully underwent surgery, with very minimal postoperative pain, stayed in hospital for average 10 days, returned to work after 3 weeks. The operative time, blood loss, hospital stay, surgeon's performance scale, wound hypothesis, wound cosmeses score, patient

satisfaction score, and patient quality of life were studied. The Limberg flap surgery had better clinical results regarding frequency of seroma formation and time to drain removal, pain score and early return to normal works. Out of the 40 patients operated 1 (2.5%) developed superficial skin necrosis, 2 (5%) developed seroma, and 1(2.5%) type-1 diabetic female developed surgical site infection.

Conclusion: In this procedure of Limberg flap there are significant benefits in terms of postoperative pain, infection rates, less hospital stay and early return to work with almost nil recurrences.

Keywords: Flap; Limberg; Pilonidal; Rhomboid; Sinus; Sacrococcygeal.

Introduction

Sacrococcygeal pilonidal sinus is an acquired disease most commonly affects the young adults. Male are affected twice more than female and occurs both after puberty and before the age of 40 years.¹ Commonly the sinus is seen in the gluteal cleft, however in other sites such as the umbilical, axilla and inter digital especially in barbers and other areas also rarely it manifest.² The Pilonidal sinus is diagnosed by identifying the epithelialized follicular opening of the sinus. "Pilonidal" means "nest of hairs." in Latin. It causes significant

morbidity from both disease and surgery done for the same.

The epidemiological studies shows an estimated incidence of 26 per 1,00,000 population.^{3,4} The pilonidal sinus normally presents as a cyst, abscess, or sinus tracts with or without discharge.⁵ Mayo in 1833 first reported these cases and proposed the pathogenesis is due to congenital origin secondary to the persistent remnant of an epithelial lined tract from postcoccygeal epidermal cell rests or vestigial scent cells. However this theory is disputed as congenital tracts do not contain hair and are lined by cuboidal epithelium and the view is now shifted toward acquired theory.⁶ It is now attributed to the persistent local irritations and resultant aberrations, poor hygiene, excessive hairiness and presence of deep anatomical natal cleft.⁷ The presence of high quantity of hair, extreme force, and vulnerability to infection were the three cardinal factors for the development of this disease as per the study of Karydakakis *et al.*⁸

The surgical treatment is the corner stone for this disease and various procedures like excision and packing and leaving it for secondary granulation and healing, excision and primary closure, marsupialization, and flap techniques have been suggested for the treatment.⁹

Recurrence following treatment is the major concern and it is reported regardless of the technique followed there is about 20 to 40% recurrence for this disease.¹⁰ The causes of recurrence were widely studied and postulated as leaving behind some tracts, sutures in midline causing more trauma with repeated infection with accumulation of perspiration, and friction with tendency of the hair getting incorporated into the wound.¹¹ No technique is termed as gold standard treatment method at present. An ideal operation should be simple, with less hospital stay, low recurrence rate, with minimal pain, wound care and less the patient's time off-work and early return to works.¹²

Limberg in 1946 designed rhomboid flap for sacrococcygeal pilonidal sinus.¹³ It is a technique of closing a 60° rhombus-shaped defect with a transposition flap. As this flap was easy to perform, with sutures away from the midline giving rise to a tensionless flap of unscarred skin in the midline, which helps in good hygiene maintenance, reducing sweating, maceration, erosions, and scar formation, it gained wide usage.

Literature study shows, In Limberg flap with wide rhomboid excision of the sinus and covering it with transposition flap, is much better than primary closure, or other flap coverage methods. It is also

stated to be a safe and reliable method with low complications and recurrence for the treatment of sacrococcygeal pilonidal sinus.¹⁴

In our institution the primary excision of the sinus and through curetting followed by dressing to enhance granulation and secondary healing was followed. As this method postulated had much appreciated quicker relief we resorted to carry on this study in our setup to evaluate the usefulness of Limberg flap procedure in sacrococcygeal pilonidal sinus, patient compliance, complications, and long-term recurrence rates following the procedure.

Methods

The study was performed in the General surgical unit of Kanyakumari Government Medical college Hospital from January 2017 to December 2019 and total 40 patients (34 male and 6 female) were included in the study.

An informed written consent was obtained prior to surgery.

Inclusion criteria

- Sacrococcygeal pilonidal disease.
- Age between 16 and 50 years.
- Primary or recurrent disease.
- Willing for the study.

Exclusion criteria

- Unfit for surgery.
- Unwilling.
- Severe co morbidities and bleeding disorders.

All patients were prospectively evaluated for age, gender, indication of surgery, duration of symptoms, co morbidities, and location of sinus, operative time, postoperative stay and complications.

The study was approved for ethical clearance by the ethical committee of the Medical College.

Procedure

Patients who had pilonidal abscess were first managed by incision and drainage they later underwent definitive surgery. Surgery was performed under general or regional anaesthesia.

Patients were placed in prone jack-knife position with buttocks strapped for wide exposure.

After painting and draping, the area to be excised is marked and flap lines are marked so as to be able to excise all of the pits and sinuses enbloc. Care was also taken to leave minimum midline scar (Fig. 1).

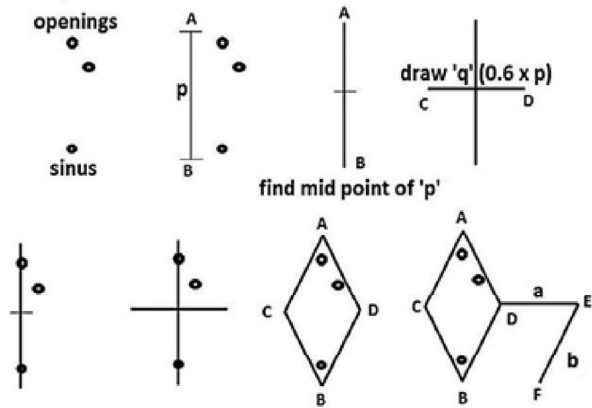


Fig. 1: General schematic of creating a limberg flap.

The long axis of the rhomboid in midline is marked as A-B, B being adjacent to peri anal skin, A and B are marked such that all diseased tissues can be included in the excision. The line C-D transects the midpoint of A-B at right angles and is 60% of its length. D-E is a direct continuation of the line C-D and is of equal length to the incision C-A, to which it will be sutured after rotation. E-F is parallel to D-B and of equal length. After rotation, it will suture to A-D. (Fig. 2).

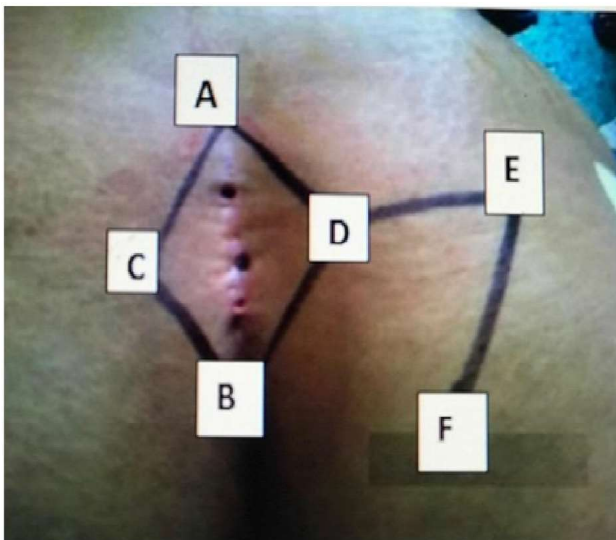


Fig. 2: Markings for creating Limberg flaps

The rhomboid incision with each side equal in length, includes the sinus, is made down to the presacral fascia. The flap is constructed by extending the incision laterally down to the fascia of the gluteus maximum muscle (Fig. 3).

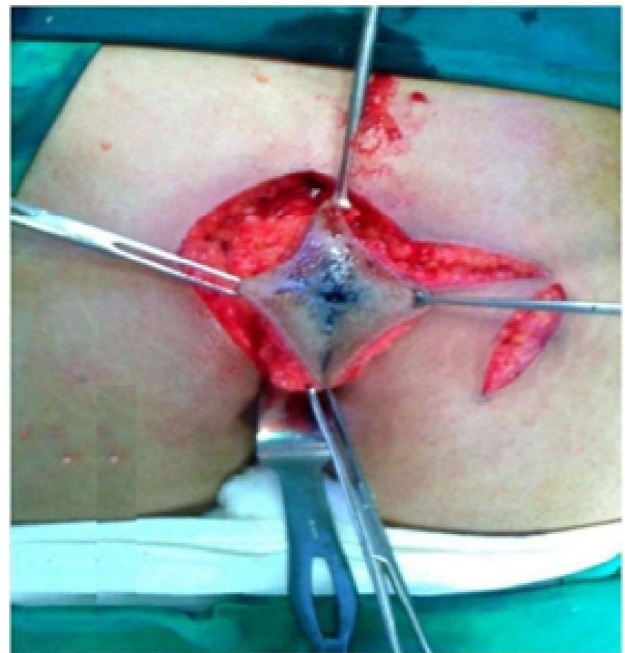

Fig. 3: Excision till deep fascia

After securing the haemostasis the flap is transposed to the rhomboid defect created by excision of the sinus (Fig. 4).

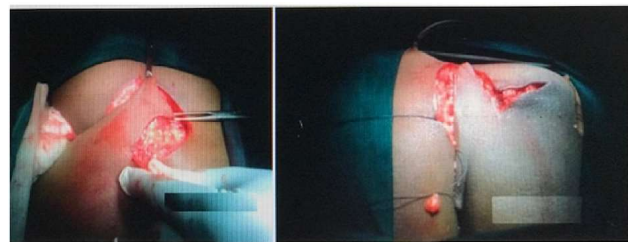


Fig. 4: Rising of flap and rotating over the defect

Subcutaneous tissue is approximated with interrupted vicryl 2-0 suture with a drain fixed. The skin is approximated with interrupted nylon 3-0 suture (Fig. 5).

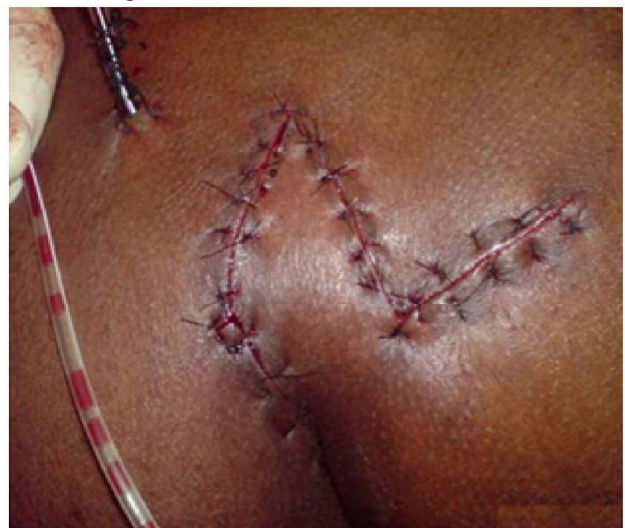

Fig. 5: Final outcome after suturing

Drain is removed after 48–72 hours. Alternate sutures are removed on 9th postoperative day (POD). Rests of the sutures are removed on the 10th day. Postoperatively patients are advised to avoid prolonged sitting or exercise for two weeks. The general cleanliness and keeping the area dry and remove the dense hair if any for one month. Patients are followed up in OPD monthly for 6 months. Length of hospital stay, time taken for return to work, postoperative complications and recurrence were recorded.

Results

Forty patients were operated by rhomboid excision and Limberg flap reconstruction. Among them there were 34 males (85%) and 6 females (15%). The mean age of presentation was 28 years old (range 16–50 years old). Seven patients presented

with recurrent sinus (17.5%). Twenty five patients (62.5%) presented with discharge, 10 patients (25%) presented with pain, four (10%) with infection and one with pilonidal abscess. The operative time ranged from 60 to 100 minutes. Hospital stay ranged from 10 to 12 days. The demographic profile and intraoperative details are tabulated in Table 1.

Out of the 40 cases that were operated, 1(2.5%) developed superficial skin necrosis at the tip of the rhomboid flap (<1 cm), 2 (5%) developed seroma postoperatively which resolved with conservative treatment, and 1 (2.5%) type-1 diabetic female developed wound infection which was treated by laying open of a single suture and allowing to heal by secondary intention. None of them required any surgical intervention. No recurrences were noted in the follow up period ranging from 12 months to 2 years. The complications noted in our study are tabulated in Table 2.

Table 1: General, demographic and clinical data

Variable	Value
Age	28 years (16-50)
Gender	
Male	34 (85.1%)
Female	6 (15%)
Number of sinuses	
Single midline	28 (70.8%)
Multiple midline	12 (30%)
Co morbidities	
Hirsute nature	23 (57.5%)
Obesity	1 (2.5%)
Smoking	4 (10%)
Symptoms	
infection	4 (10%)
Pain	10 (25%)
Discharge	25 (62.5%)
Duration of symptoms	6.52 months (2-13)
Operative time	67.05 min (60-90)
Post op stay	10.05 days (9-12)

Table 2: Complications

	Number	Percentage
Hematoma	0	0
Superficial skin necrosis	1	(2.5%)
Wound gaping	0	0
Flap edema	2	(5%)
Seroma	2	(5%)
SSI	1	0
Recurrence	0	(2.5%)

Table 3: Comparison of results with other studies

Author/s	Patients (no.)	Hospital stay (days)	Complication (%)	Recurrence (%)
Katsoulis et al. [23]	25	4.0	4 (16%)	1(4%)
Akin et al. [20]	411	1-10	15.75%	12 (2.91%)
Urhan et al. [25]	110	3-7	7%	5 (4.9%)
Mentes et al. [2]	353	2-19	11%	11 (3.1%)
Aslam et al. [24]	110	3.0	5%	1 (.9%)
El-khadrawy [21]	60	5-11	40%	6 (10%)
U Jethwani et al.	67	9-12	11.94%	1 (1.49%)
Current study Jayalal et al.	40	10-12	3 (7.5%)	0

Discussion

Pilonidal sinus diseases are caused by forces exerted on the midline of the natal cleft (tension = force/surface area) especially on the point of coccyx turning anteriorly¹⁴, vacuum effect created between the buttocks, by virtue of it the anaerobic bacteria are gravitated to this point along with hair or debris¹⁵, the ensuing friction movement of buttocks¹⁶ in the presence of other risk factors such as obesity, hirsutiness, and bad hygiene.¹⁷ An effective surgical technique will eliminate this shearing forces, vacuum effect, and friction movement.¹⁸

Excision of the diseased tissue down to the sacrococcygeal fascia is the standard prerequisite for an effective surgical treatment for this sinus. However the next step of what to do with defect is a matter of concern and debate. The patient compliance, postoperative pain, infection, recurrence rates, hospital stay, frequent wound dressings, and cosmetic outlook with preservation of the bottom are the main criteria which decide the surgical option.

Recurrence is the main problem associated with all modalities of surgeries used in the treatment for pilonidal sinus which ranged from 21.4% to 100% for incision and drainage, 5.5%-33% for excision and open packing, 8% for marsupialisation, 3.3%-11% for Z plasty.¹⁹ Flap techniques have been associated with lower recurrence rates.

Limberg flap has many advantages as it is easy to perform, design and flattens the natal cleft with a large well-vascularised pedicle which is sutured without tension. Also it has the benefits of reducing midline dead space and midline scar is avoided. Limberg flaps are useful in recurrent pilonidal disease and reduce hospital stay and time to resume normal activities. The Lamberg flap procedure was found much better than simple excision and closure, marsupialization, or other postulated flap procedures such as Bescom and Karydakis.^{8,15}

The review of various reported studies on this technique were compared with our study report and most of the factors are comparable. In our study, 40 patients with sacrococcygeal pilonidal disease were managed with rhomboid excision and Limberg flap reconstruction. No recurrence was noted in this study. Akin *et al.*²⁰ operated on 411 patients and reported recurrence rates of 2.91%. Superficial necrosis was seen in one patient (1.49%), which may be due to the design of the long flap or fault technique. El-khadrawy²¹ operated on 40 patients and had superficial necrosis at the tip of the flap in four patients (10%). Time off-work in our study patients was 12-18 days. This was similar to that reported by Abu Galala et al.²² Katsoulis had 25 patients, with 16 of them having complications with no recurrences.²³ Aslam had 110 patients, with 5 of them having complications and 1 recurrence.²⁴ The comparative table of various studies and reported complications are tabulated in (Table 3).

Conclusion

Sacrococcygeal pilonidal sinus is a treacherous disease for both the patient and the surgeon by virtue of its recurrent infection, persistent troublesome pain with discharge, and high recurrence rates inspite of good surgical procedures. Following Limberg flap reconstruction after excision of the pilonidal sinus, the resultant distortion and shape of the gluteal regions are averted and as there is no recurrence the agonizing continuous discharge of foul smelling pus are stopped.

The technique is easy to perform in quick time by the General surgeons and this procedure can be used in both primary and recurrent diseases, with very low complication rates. The advantages are obliteration of the midline natal cleft and scar pressure in the midline, quick healing time, short hospital stay, and early return to daily life. It is a feasible best option for the sacrococcygeal pilonidal sinuses.

References

1. Hull TL, Wu J. Pilonidal disease. *Surg Clin North Am.* 2002;82:1169–1185. doi: 10.1016/S0039-6109(02)00062-2.
2. Menten O, Bagci M, Bilgin T, Ozgul O, Ozdemir M. Limberg flap procedure for pilonidal sinus disease: results of 353 patients. *Langenbecks Arch Surg.* 2008;393(2):185-9.
3. Humphries AE, James E. Evaluation and management of pilonidal disease. *Surg Clin North Am.* 2010;90(1):113–124. doi: 10.1016/j.suc.2009.09.006.
4. Sondena K, Andersen E. Patient characteristics and symptoms of in chronic pilonidal sinus disease. *Int J Colorectal Dis.* 1995;10(1):39–42. doi: 10.1007/BF00337585.
5. Clothier PR, Haywood IR. The natural history of the post anal pilonidal sinus. *Ann R College Surg England.* 1984;66(3):201–203.
6. Brearley R. Pilonidal sinus: a new theory of origin. *Br J Surg.* 1955;43:62–68. doi: 10.1002/bjs.18004317708.
7. Bascom J. Pilonidal disease: origin from follicles of hairs and results of follicle removal as treatment. *Surgery.* 1980;87:567–572.
8. Karydakakis GE. Easy and successful treatment of pilonidal sinus after explanation of its causative process. *Aust NZJ Surg.* 1992;62:385–389 doi: 10.1111/j.1445-2197.1992.tb07208.x.
9. Mohamed HA, Kadry I, Adly S. Comparison between three modalities for non-complicated pilonidal sinus disease. *Surgeon.* 2005;3(2):73-77. doi: 10.1016/S1479-666X(05)80065-4.
10. Berger A, Frileux P. Pilonidal sinus. *Ann Chir.* 1995;49:889–901.
11. Casetecker J, Mann BD, Castellanes AF, Strauss J (2006) Pilonidal disease. <http://emedicine.medscape.com/article192668>. Accessed 11 Dec 2011.
12. Solla JA, Rothenberger DA. Chronic pilonidal disease. An assessment of 150 cases. *Dis Colon Rectum.* 1990 Sep;33(9):758-61.
13. Wolfe SA, Limberg AA, M.D., 1894-1974. Plastic and reconstructive surgery. 1975;56(2):239–240.
14. Brazier JE, Harper R, Jones NM, O’Cathain A, Thomas KJ, Usherwood T, Westlake L. Validating the SF-36 health survey questionnaire: new outcome measure for pri care. *BMJ* 1992; 305:160-164.
15. Bascom JU. Pilonidal sinus. *Curr Pract Surg* 1994; 6:175-180.
16. Lee HC, Ho YH, Seow CF, Eu KW, Nyam D. Pilonidal disease in Singapore: clinical features and Management. *Aust N Z J Surg.* 2000;70:196-98.
17. Akinci OF, Bozer M, Uzunkoy A, et al. Incidence and aetiological factors in pilonidal sinus among Turkish soldiers. *Eur J Surg.* 1999;165:339-342.
18. Harlak A, Menten O, Kilics S, et al. Sacrococcygeal PSD: analysis of previously proposed risk factors. *Clinics.* 2010;65:125-31.
19. Jensen SL, Harling H. Prognosis after simple incision and drainage for a first-episode acute pilonidal abscess. *Br J Surg.* 1988 Jan;75(1):60-1.
20. Akin M, Gokbayir H, Kilic K, Topgul K, Ozdemir E, Ferahkose Z. Rhomboid excision and Limberg flap for managing pilonidal sinus: long-term results in 411 patients. *Colorectal Dis.* 2008 Nov;10(9):945-8.
21. El-khadrawy OH. The rhomboid flap for recurrent pilonidal disease. *Tanta Med Sci J.* 2006 Oct;1(4):175-81.
22. Abu Galala KH, Salam IM, Abu Samaan KR, El Ashaal YI, Chandran VP, Sabastian M. Treatment of pilonidal sinus by primary closure with a transposed rhomboid flap compared with deep suturing: a prospective randomised clinical trial. *Eur J Surg.* 1999 May;165(5):468-72.
23. Katsoulis IE, Hibberts F, Carapeti EA. Outcome of treatment of primary and recurrent pilonidal sinus with Limberg flap. *Surgeon.* 2006;4(1):7–10
24. Aslam M, Choudhry A. Use of Limberg flap for pilonidal sinus – a viable option. *J Ayub Med Coll Abbottabad.* 2009 Oct-Dec;21(4):31-3. [PubMed].
25. Urhan MK, Kucukel F, Topgul K, Ozer I, Sari S. Rhomboid excision and Limberg flap for managing pilonidal sinus: results of 102 cases. *Dis Colon Rectum.* 2002 May;45(5):656-9.