

## Metastatic Breast Cancer to the Uterine Cervix Mimicking Cervical Cancer

Amritjot Singh Randhawa<sup>1</sup>, Amritpal Singh Bhatia<sup>2</sup>

**Author's Affiliation:** <sup>1</sup>Assistant Professor, Department of Radiotherapy and Oncology, <sup>2</sup>Assistant Professor, Department of General Surgery, SGRDIMS, Amritsar, Punjab 143501, India.

**Corresponding Author:** Amritjot Singh Randhawa, Assistant Professor, Department of Radiotherapy and Oncology, SGRDIMS, Amritsar, Punjab 143501, India.

**E-mail:** dramritrandhawa@gmail.com

### How to cite this article:

Amritjot Singh Randhawa, Amritpal Singh Bhatia. Metastatic Breast Cancer to the Uterine Cervix Mimicking Cervical Cancer. Indian J Canc Educ Res 2020;8(1):49-52.

### Abstract

Metastasis to uterine cervix is a complication of breast cancer that is not commonly known. Detection of cervical metastasis before the diagnosis is even rarer. The present report describes a case of a 50 years old woman who had a large cervical growth mimicking a primary of cervix. However, simultaneously she also presented with bilateral breast lumps of one and half years duration. Histopathological examination of the cervical tumour showed patterns characteristics of invasive lobular carcinoma of the breast which was already diagnosed as the primary in the breast. She underwent chemotherapy and achieved good response.

**Keywords:** Breast cancer; Cervix; Lobular carcinoma; Metastasis.

### Introduction

Metastasis to the female genital tract from extragenital primary cancers is uncommon. When they occur, the ovaries are most often affected, and the uterus, especially the uterine cervix, is rarely involved by metastatic tumours.<sup>1</sup> Invasive lobular carcinoma (ILC) spreads to gynaecologic organs more frequently than invasive ductal carcinoma.<sup>2</sup> ILC is more likely to be multi-centric, bilateral and has an increasing incidence in postmenopausal women.<sup>3</sup> Although pathologically distinct, ILC appears to have similar clinical outcomes and prognosis as infiltrating ductal carcinoma (IDC) of the breast.<sup>4</sup>

We herein report a rare case of extensive metastasis of primary ILC of breast to multiple gynecological sites.

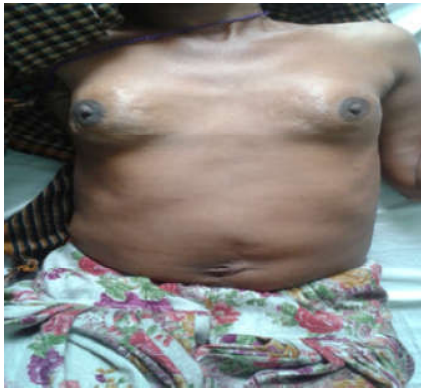### Case Report

A 50 year old post-menopausal female presented with bilateral breast lumps from one and a

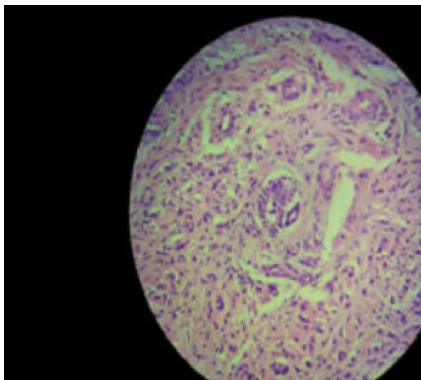
half years and abdominal distension. She also complained of increased frequency of micturition for duration of six months. On clinical examination bilateral breasts were hard, nodular with peau d'orange appearance and fixed to chest wall, along with bilateral axillary lymphadenopathy (Fig. 1). FNAC from the breast lump was performed which was suggestive of low grade lobular carcinoma. On per vaginal examination, both the cervical lips were infiltrated with growth. Fornices were shallow but free, and vaginal walls were smooth. On per rectal examination bilateral parametria was involved just short of lateral pelvic wall. On MRI imaging, both ovaries were bulky with evidence of multiple follicles. Uterus measured 7.7x4.5x5.4cms. Gross ascites was seen, malignant cytology from the fluid however was negative. There was evidence of diffuse thickening of recto-sigmoid colon with maximum wall thickness 6.7mm. There were multiple enlarged superficial inguinal lymph nodes. She underwent exploratory laparotomy. Diffuse carcinomatosis was identified. Biopsies were taken from multiple sites including



fallopian tube and omentum. Ascitic fluid was collected. Cervical and endometrial biopsies were taken. The diagnosis of metastatic ILC was made through gross histopathological examination and immunohistochemistry (IHC) staining. Microscopic examination of the tissues showed carcinoma cells displaying the linear, "Indian-file" arrangement characteristic of ILC of the breast with rare cells of the "signet ring" type (Fig. 2). Further IHC staining showed that 95% of cells taken from all metastatic sites were highly positive for cytokeratin 7 (CK) and gross cystic disease fluid protein (GCDPF 15).



**Fig. 1:** Patient's bilateral breasts are hard, nodular with peau d'orange appearance and fixed to chest wall, along with bilateral Axillary lymphadenopathy.



**Fig. 2:** Microscopic examination of the tissues shows carcinoma cells displaying the linear, "Indian-file" arrangement characteristic of ILC of the breast with rare cells of the "signet ring" type.

Further, estrogen (ER) and progesterone receptors (PR) were positive in 80% of tumor cells. These findings were consistent with a diagnosis of ILC of breast with metastases to the omentum, fallopian tube, endometrium and cervix.

Keeping in view the extensive metastasis the patient was given gemcitabine along with paclitaxel regimen for 6 cycles which is the first

line chemotherapy in metastatic breast cancer. All cycles of chemotherapy were given in outpatient setting. Gemcitabine was given in dose of 1.4gm i.v. followed by paclitaxel 260 mg i.v. Cycles were repeated every 21 days. The patient tolerated chemotherapy well with one or two episodes of post chemotherapy neutropenia which was corrected by giving growth factors. It resulted in good response in that the size of lumps of both breasts decreased, ascites was resolved, cervix became soft and bulk of abdominal mass decreased. The patient was planned for subsequent modified radical mastectomy (MRM) which was successful and the patient is now being planned for MRM in the contralateral breast. Till the time of last follow up, the patient was ECOG - 1 with no evidence of progression of the disease.

## Discussion

Breast cancer continues to be the most common carcinoma diagnosed in women (30% of all cancers),<sup>5,6</sup> and is the second leading cause of cancer deaths in women.<sup>6</sup>

ILC is the second most common histology of invasive breast cancers diagnosed (15%),<sup>3</sup> and has a rising incidence in postmenopausal women,<sup>8</sup> which may be related to hormone replacement therapy.<sup>9</sup> It is more likely to be multicentric and bilateral.<sup>3,8,10,11</sup> Due to standardized screening protocols and improved imaging technology, most of the tumours are detected early and only 10% of breast cancers present as metastatic disease.<sup>12,13</sup> But at the same time mammographic findings are often nonspecific,<sup>4,14</sup> leading to a known propensity for ILC to present at a later stage, with synchronous bilateral or metastatic disease.<sup>15</sup>

In comparing the metastatic patterns of ILC versus IDC, Borst et al. found that ILC was significantly more likely to spread to the GI tract, gynecologic organs, peritoneal surface, and retroperitoneum<sup>16</sup> but metastasis to cervix is extremely rare.<sup>17</sup> The reason for its rarity are that the cervix is a small target organ with a small blood supply and only an afferent lymph drainage system.<sup>18</sup> The fibromuscular tissue of the cervix is a poor culture medium. Most of the extragenital metastasis to cervix arises from primary tumours of the gastrointestinal tract, lung, pancreas, melanoma, urethra. Only 4.5% of cervical secondaries arise from breast primaries.

Mazur et al. reported that, among 149 metastatic tumours to the female genital tract from extragenital primaries, the ovary and vagina were the most

frequent locations of metastases (75.8% and 13.4%, respectively), and only 8.1% were to the uterus (4.7% to the endometrium, 3.4% to the cervix).<sup>1</sup> Breast was the second most common primary site next to gastrointestinal tumours. Limoine and Hall found 33 cases of distant metastasis to the cervix, four of which (12.1%) were from a breast primary.<sup>19</sup> In our case we noted metastasis to the fallopian tube, endometrium and cervix, but not to the ovary and vagina.

Although pathologically distinct from infiltrating ductal carcinoma in terms of local and distant spread,<sup>20,21</sup> ILC appears to have similar clinical outcomes and prognosis as infiltrating ductal carcinoma (IDC) of the breast.<sup>22</sup> This has led to the suggestion that ILC be treated in the same multimodality fashion as IDC.<sup>23</sup>

It is important to consider metastatic ILC in the diagnostic evaluation of peritoneal surface malignancies (PSM). Although metastasis from an ovarian or intestinal primary<sup>24</sup> or primary peritoneal tumours<sup>25</sup> are high on the differential for PSM, our review of the literature demonstrates that a high index of suspicion for metastatic ILC must be maintained in this situation. Peritoneal involvement from metastatic breast cancer carries a poor prognosis, with a median survival (MS) in a series of 44 patients reported by Tuthill et al. of 1.5 months as compared to a 20.5 months MS for patients with metastatic breast cancer at other sites.<sup>26</sup>

Due to the rarity of this disease entity, there is no standardized approach to management of PSM arising from a primary breast cancer, although current approaches to gynaecologic<sup>27</sup> and intestinal<sup>28,29</sup> PSM suggest that complete cytoreduction and heated intraperitoneal chemotherapy may provide a survival advantage.

While there are no studies evaluating aggressive surgical management of PSM or evaluating strategies for gynaecologic, GI tract and peritoneal evaluation to be implemented for patients with ILC, this case report raises an interesting prospective area of study. First line chemotherapy with Gemcitabine and paclitaxel has proved to be beneficial in this particular case with significant response. Due to the unique characteristics of ILC, we propose a closer follow up.

## Conclusion

ILC of the breast is a distinct pathologic entity as compared to IDC. ILC harbours increased potential for late local recurrence and metastatic disease to omentum and gastrointestinal tract and gynaecological organs especially ovaries and metastasis to cervix is rare.<sup>30,31</sup>

To illustrate these situations, we presented a typical case of ILC metastatic spread to the fallopian tubes, endometrium, cervix and peritoneal surface.

We propose that in patients with a known history of ILC, a high index of suspicion for metastatic disease needs to be entertained. In addition, metastatic ILC should remain high on the differential in female patients presenting with gynaecologic malignancies of unknown origin.

Physicians need to be cognizant of this metastatic masquerade and we advocate closer follow up and specifically more intense gynaecologic follow up for patients diagnosed with ILC and intensive treatment with chemotherapy.

*Prior publication:* Nil

*Support:* Nil

*Conflicts of interest:* Nil

*Permissions:* Nil

## References

1. Mazur MT, Hsueh S, Gersell DJ. Metastases to the female genital tract: analysis of 325 cases. *Cancer* 1984;53:1978-1984.
2. Lamovec J, Bracko M. Metastatic pattern of infiltrating lobular carcinoma of the breast: An autopsy study. *J Surg Oncol*. 1991;48:28-33.
3. Fortunato L, Mascaro A, Poccia I et al. Lobular breast cancer: same survival and local control compared with ductal cancer, but should both be treated the same way? Analysis of an institutional database over a 10-year period. *Ann Surg Oncol* 2012;19:1107-14.
4. Winchester DJ, Chang HR, Graves TA et al. A comparative analysis of lobular and ductal carcinoma of the breast: presentation, treatment, and outcomes. *J Am Coll Surg* 1998;186:416-22.
5. Siegel R, Ward E, Brawley O. Cancer statistics, 2011: the impact of eliminating socioeconomic and racial disparities on premature cancer deaths. *CA Cancer J Clin* 2011;61:212-36.
6. Siegel R, Naishadham D, Jemal A. Cancer statistics 2012. *CA Cancer J Clin* 2012;62:10-29.
7. Li CI, Uribe DJ, Daling JR. Clinical characteristics of different histologic types of breast cancer. *Br J Cancer* 2005;93:1046-52.
8. Li CI, Anderson BO, Porter P, et al. Changing incidence rate of invasive lobular breast carcinoma among older women. *Cancer* 2000;88:2561-9.
9. Ehemann CR, Shaw KM, Ryerson AB et al. The changing incidence of in situ and invasive ductal and lobular breast carcinomas: United States, 1999-2004. *Cancer Epidemiol Biomarkers Prev* 2009;18:1763-9.

10. Intra M, Rotmensz N, Viale G et al. Clinicopathologic characteristics of 143 patients with synchronous bilateral invasive breast carcinomas treated in a single institution. *Cancer* 2004;101:905-12.
11. Lesser ML, Rosen PP, Kinne DW. Multicentricity and bilaterality in invasive breast carcinoma. *Surgery* 1982;91:234-40.
12. Le Gal M, Ollivier L, Asselain B et al. Mammographic features of 455 invasive lobular carcinomas. *Radiology* 1992;185:705-8.
13. Krecke KN, Gisvold JJ. Invasive lobular carcinoma of the breast: mammographic findings and extent of disease at diagnosis in 184 patients. *AJR Am J Roentgenol* 1993;161:957-60.
14. Kurtz JM, Jacquemier J, Torhorst J et al. Conservation therapy for breast cancers other than infiltrating ductal carcinoma. *Cancer* 1989; 63:1630-5.
15. Santiago RJ, Harris EE, Qin L, et al. Similar long-term results of breast-conservation treatment for Stage I and II invasive lobular carcinoma compared with invasive ductal carcinoma of the breast: The University of Pennsylvania experience. *Cancer* 2005;103:2447-54.
16. Winston CB, Hadar O, Teitcher JB et al. Metastatic lobular carcinoma of the breast: patterns of spread in the chest, abdomen, and pelvis on CT. *AJR Am J Roentgenol* 2000;175:795-800.
17. Borst MJ, Ingold JA. Metastatic patterns of invasive lobular versus invasive ductal carcinoma of the breast. *Surgery* 1993;114:637-41.
18. Bogliolo S, Morotti M, Valenzano Menada M, et al. Breast cancer with synchronous massive metastasis in the uterine cervix: a case report and review of the literature. *Arch Gynaecol Obstet* 2010;281:769-773.
19. Limoine NR, Hall PA. Epithelial tumors metastatic to the uterine cervix. A study of 33 cases and review of the literature. *Cancer* 1986; 57:2002-2005.
20. Hussein MI, Anwar IF, Down SK et al. Invasive lobular carcinoma of the breast: should this be regarded as a chronic disease? *Int J Surg* 2010; 8:346-52.
21. Harris M, Howell A, Chrissohou M et al. A comparison of the metastatic pattern of infiltrating lobular carcinoma and infiltrating duct carcinoma of the breast. *Br J Cancer* 1984; 50:23-30.
22. Arpino G, Bardou VJ, Clark GM et al. Infiltrating lobular carcinoma of the breast: tumor characteristics and clinical outcome. *Breast Cancer Res* 2004;6:149-56.
23. Ferlicot S, Vincent-Salomon A, Medioni J et al. Wide metastatic spreading in infiltrating lobular carcinoma of the breast. *Eur J Cancer* 2004;40:336-41.
24. Levy AD, Shaw JC, Sobin LH. Secondary tumors and tumor like lesions of the peritoneal cavity: imaging features with pathologic correlation. *Radiographics* 2009;29:347-73.
25. Levy AD, Arnaiz J, Shaw JC et al. From the archives of the AFIP: primary peritoneal tumors: imaging features with pathologic correlation. *Radiographics* 2008;28:583-607.
26. Tuthill M, Pell R, Guiliani R et al. Peritoneal disease in breast cancer: a specific entity with an extremely poor prognosis. *Eur J Cancer* 2009;45:2146-9.
27. Bijelic L, Jonson A, Sugarbaker PH. Systematic review of cytoreductive surgery and heated intraoperative intraperitoneal chemotherapy for treatment of peritoneal carcinomatosis in primary and recurrent ovarian cancer. *Ann Oncol* 2007; 18:1943-50.
28. Cole KL, Choudry HA, Jones HL, et al. Critical role of hyperthermic intraperitoneal chemoperfusion in the treatment of a patient with Pseudomyxoma peritonei. *J Surg Oncol* 2012 doi: 10.1002/jso.23088.
29. Verwaal VJ, Bruin S, Boot H, Van Slooten G, et al. 8-year follow-up of randomized trial: cytoreduction and hyperthermic intraperitoneal chemotherapy versus systemic chemotherapy in patients with peritoneal carcinomatosis of colorectal cancer. *Ann Surg Oncol* 2008;15:2426-32.
30. Neal L, Sookhan N, Reynolds C. Occult breast carcinoma presenting as gastrointestinal metastases. *Case Report Med* 2009:564756.
31. McLemore EC, Pockaj BA, Reynolds C, et al. Breast cancer: presentation and intervention in women with gastrointestinal metastasis and carcinomatosis. *Ann Surg Oncol* 2005;12:886-94.