

# Innovative Use of Autologous Platelet Rich Plasma as Preservative Media for Skin Graft

Barath Kumar Singh P<sup>1</sup>, Ravi Kumar Chittoria<sup>2</sup>

## How to cite this article:

Barath Kumar Singh P, Ravi Kumar Chittoria/Innovative Use of Autologous Platelet Rich Plasma as Preservative Media for Skin Graft/Journal of Plastic Surgery and Transplantation. 2023;4(1):23-26.

## Abstract

**Objectives:** In this study we have assessed the viability of skin grafts stored using autologous platelet rich plasma. To assess the usage of Autologous platelet rich plasma as a storage medium for Skin graft.

**Materials and Methods:** The Skin graft was harvested from the patient who underwent surgery in hospital. The harvested skin grafts are stored in the medium with autologous platelet rich plasma. Autologous platelet rich plasma has rich source of proteins and growth factors. The autologous platelet rich plasma was prepared from the patient own blood. The histological changes of the skin graft were assessed periodically on day 7, 14 and day 21.

**Results:** Autologous platelet rich plasma stored skin graft were able to preserve the histological changes of stored skin grafts on day 7, 14 and day 21.

**Conclusion:** Preserved skin grafts can either be used in staged reconstructive procedures as autografts or for temporary coverage of wounds as allografts. Although several nutrient media and techniques have been developed for storage, the innovative use of autologous platelet rich plasma as a promising storage medium is successful.

**Keywords:** Innovative; Autologous platelet rich plasma; Preservative; Medium; Storage; Skin graft.

## INTRODUCTION

Most of the Skin grafts harvested from the patients has epidermal and upper dermal layer. The harvested and stored human skin grafts has been used in burn wounds, large wounds in the extremity or any other region of the body if needed as an allograft. Human Skin has five layers of epidermis and upper part of papillary dermis. The Skin allograft has low immunogenic potential, anti-inflammatory nature, antioxidant properties, and also angiogenic properties. These features make

---

**Author Affiliation:** <sup>1</sup>Senior Resident, Department of Plastic Surgery, <sup>2</sup>Professor & Head, Department of Plastic Surgery & Telemedicine, Jawaharlal Institute of Postgraduate Medical Education and Research, Pondicherry 605006, India.

**Corresponding Author:** Ravi Kumar Chittoria, Professor & Head, Department of Plastic Surgery & Telemedicine, Jawaharlal Institute of Postgraduate Medical Education and Research, Pondicherry 605006, India.

**E-mail:** drchittoria@yahoo.com

**Received on:** 29-12-2022

**Accepted on:** 10.01.2023

skin allograft as suitable material for a biological dressing of the wound, especially for chronic wounds.<sup>1</sup> The storage of skin grafts is the important process for future usage, they are various medium, process available. In our study, we assess the role of autologous platelet rich plasma (APRP) in the preservation of skin grafts.

## MATERIALS AND METHODS

This study was done in Department of Plastic Surgery, at tertiary care hospital. Split thickness skin grafts were harvested from the patient who had undergone grafting procedure for a scalp defect. The grafts were harvested and stored in the Autologous platelet rich plasma. The skin graft piece was washed with sterile normal saline followed by heparin and gentamicin saline adequately to was stored in patient's own APRP. The specimen was stored in the refrigerator at +4° C. The small piece from the stored graft was sent for biopsy to examine the histological changes on days 7, 14 and 21. 1x1 cm skin graft piece was sent as specimen to pathologist and remaining graft was stored again in Autologous platelet rich plasma (APRP) each

time. All histological examination was performed by the same histologist.

### Preparation of APRP

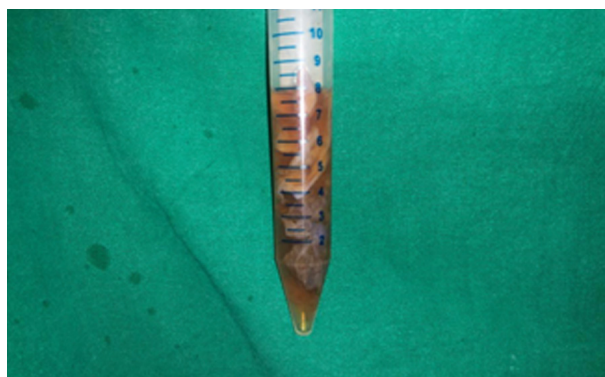
After getting consent from patient 15 ml of blood taken and centrifuged at 3000 rpm for 10 mins. The upper 2/3<sup>rd</sup> fluid is taken and again centrifuged at 4000 rpm for 10 mins. The lower 1/3<sup>rd</sup> fluid which is rich in platelet concentration is taken and used for storage of skin graft.<sup>2</sup>

## RESULTS

The Skin grafts stored in the APRP medium after harvesting from the body and stored in the refrigerator in +4°C. The small piece of skin grafts was taken from the stored graft and sent for histological examination. The histological examination of the specimen was done on day 7, day 14, and day 21. The normal architecture of the skin was maintained in all three specimens on day 7, day 14 and day 21. Autologous Platelet Rich Plasma (APRP) plays effective and economical role in the storage of skin graft without any major distortion in the architecture of the skin graft.

**Table 1:** Histological changes of stored skin graft in APRP.

Histology	Day 7	Day 14	Day 21
Integrity of epidermis	Normal Limits	Epidermis thinned out, mild pigment incontinence.	Epidermis thinned out, orthokeratosis, mild pigment incontinence
Ballooning of epithelial cells	No ballooning of cells	No ballooning of cells	No ballooning of cells
Dermis	Normal Limits	Normal limits	Normal limits
Collagen	Intact collagen	Intact collagen	Intact collagen
Basement Membrane	Intact	Intact	Intact



**Fig. 1:** Skin grafts stored in Autologous platelet rich plasma (APRP)

## DISCUSSION

Preservation of the skin allograft gives time for testing the serological status of the donor and

microbiological testing of the membrane. There are various methods to preserve the skin allograft like direct storage, cryopreservation, glycerol, preservative medium, culture medium. The ideal way of preservation is one that is easy to carry out, safe to tissue, and does not cause any alteration in the biological properties of skin.<sup>3</sup> Cryopreservation is one of the commonly used methods for the preservation of skin. It is then stored in a storage medium at a very low temperature. Different cryomedia and storage temperatures ranges have been mentioned in the literature. The most common technique of cryopreservation involves the use of glycerol as a cryoprotectant medium along with antimicrobial agents and storage at a temperature of -80°C.<sup>4</sup> There is not an ideal or universally acknowledged medium for the preservation of skin grafts. In previous studies, Roswell Park Memorial Institute 1640 solution (RPMI) was reported

superior to other media including Eagle's minimal essential medium, Euro-Collins preservation fluid, University of Wisconsin solution, Histidine-tryptophan ketoglutarate solution, and saline.<sup>5,6</sup> Basaran et al. explained this superiority with the rich amino acid content of RPMI, which helps to improve cell preservation. It is suggested that Roswell Park Memorial Institute 1640 solution (RPMI) seemed to be the most efficient short-term solution. On the other hand, storage at 4-8°C after wrapping the graft in physiological saline soaked gauze is still a widely used method by most clinicians because of practicality and inexpensiveness.<sup>7</sup> However, this solution is known to be inferior to others. In the present study, we aimed to identify histological changes of the human skin grafts stored in autologous platelet rich plasma.

Storage of skin grafts with saline moistened gauze and using it later as a homograft or autograft is a widespread practice in plastic surgery. Recent studies have reported an increase in the quality and viability of skin grafts using different storage media and, as saline lacks the nutrients necessary for cellular metabolism, this practice should be reviewed. Percentage graft take can be used to test the effects of different storage media on skin graft viability, but this may be affected by many factors other than viability such as infection, immobilization of the graft and hematoma, and so cannot be used as a primary measurement.<sup>8</sup> We assess the viability of autologous platelet rich plasma stored skin grafts. Plasma is a physiological fluid which can supply physiological concentrations of electrolytes and nutrients to a basal level of cellular metabolism and can buffer acid metabolites. The results of this study showed that plasma maintained a better environment for skin grafts by increasing the quality and survival time of skin grafts. The complication of storing the skin grafts may be infection, as plasma is a good medium for bacterial growth, but we did not observe any bacteria in our skin grafts during microscopic examination. A graft from a member of the same species but from a genetically distinct source is referred to as "allograft." When he used both his own skin and the patient's skin to heal burn wounds, George Pollock first introduced the idea. The allograft gradually vanished from the wound even though grafts took well.<sup>8</sup> Girdner was the first to discuss the application of cadaveric skin to cover burn wounds after ten years. The use of allograft skin for the cover of burn wounds and other non-healing ulcers has since been the subject of numerous research that have been published. The allograft reduces the risk of wound infection and stops protein,

fluid, and electrolyte loss from the wound, which saves the patient's energy. Additionally, it lessens discomfort while also enhancing the patient's overall wellbeing and psychological condition and preserving autografts. Allograft skin has only ever been used to cover large burn wounds in order to prepare the wound bed. According to Snyder et al., allografts have been used to treat diabetic, venous, arterial, post-traumatic, post-scleroderma, and other ulcers.<sup>9</sup> He lists a number of advantages, such as a significant decline in wound infection, desiccation, and patient sensations like discomfort. Allografts made of human skin efficiently reduce protein, electrolyte, and water loss from wounds as well as the body's need for energy, which lowers necrotizing fasciitis morbidity. The following clinical signs and symptoms point to the use of skin allografts in necrotizing fasciitis:

1. Coverage of extensive full thickness wounds.
2. Coverage of widely meshed skin autografts
3. Healing of partial thickness wounds
4. Wound bed preparation and testing for later acceptance of autograft.

Allografts made of human skin effectively lower wound protein, water, and electrolyte losses while also lowering the body's energy needs.<sup>10</sup> We employed allograft in our case for the same reason. Compared to collagen dressing, allograft more successfully reduces pain and manages infection. The sick donor's torso, hips, thighs, and upper calves can be harvested for skin allograft.

## CONCLUSION

In conclusion, APRP maintained better histological outcomes for the preservation of human skin grafts. This is an economical means of long term storage compared to other preservative media. But further studies with larger sample size and better histological markers are needed.

## REFERENCES

1. Webster JP. Refrigerated skin grafts. *Ann Surg* 1944; 120:431-49.
2. Dhurat R, Sukesh M. Principles and Methods of Preparation of Platelet-Rich Plasma: A Review and Author's Perspective. *J Cutan Aesthetic Surg*. 2014;7(4):189-97.
3. Hurst LN, Brown DH, Murray KA. Prolonged life and improved quality for stored skin grafts. *Plast Reconstr Surg* 1984; 73: 105-10.
4. Fahmy FS, Navsaria HA, Frame JD, Jones CR, Leigh

- IM. Skin graft storage and keratinocyte viability. *Br J Plast Surg* 1993; 46:292-5.
5. Smith JW, Aston SJ (eds). *Grabb and Smith's Plastic Surgery*. 4th Edn. Boston: Little, Brown and Company, 1991.
  6. Titley OG, Cooper M, Thomas A, Hancock K. Stored skin stored trouble? *Br J Plast Surg* 1994; 47: 24-9.
  7. Greenleaf G, Hansbrough JF. Current trends in the use of allograft skin for patients with burn and reflections on the future of skin banking in the United States. *J Burn Care Rehabil*. 1994;15(5):428-431.
  8. Pollock GD. Cases of skin grafting and skin transplantation. *Trans Clin Soc Lond*. 1871; 4:37.
  9. Girdner JH. Skin grafting with grafts taken from the dead subject. *Med Rec*. 1881; 20:119-20.
  10. Zaroff LI, Mills W, Duckett JW, Switzer WE, Moncrief JA. Multiple uses of viable cutaneous homografts in the burned patient. *Surgery*. 1966;59(3):368-72.

