

Histopathological Study of Liver in Medicolegal Cases: A Tertiary Care Centre Study

Shrinivas Bharat Borkar¹, Mohammed A. Sameer², Vijaya G. Muddamwar³,
Deepak S. Sadhu⁴

How to cite this article:

Shrinivas Bharat Borkar, Mohammed A. Sameer, Vijaya G. Muddamwar. Histopathological Study of Liver in Medicolegal Cases: A Tertiary Care Centre Study. Ind J of Path: Res and Practice 2024;13(1) 19-23.

Abstract

Background: The pathological examinations of medicolegal cases is not confined to determining the cause of death but also useful in teaching pathogenesis and demography of the disease. Liver is the principal site of many metabolic activities and is vulnerable to many metabolic, toxic, microbial and circulatory insults. Due to enormous functional reserve, many liver lesions are silent till late in the course of disease.

Aims: This study aimed to analyse histopathological findings of liver diseases in medicolegal cases and correlate with clinical findings wherever available.

Methods and Material: The present study is a retrospective observational study with 262 medicolegal autopsy cases over a one-year period conducted in the Department of Pathology of a tertiary care centre. Representative tissue from the liver was collected in 10% neutral buffered formalin and sent for histopathological examination.

Results: Total 262 medicolegal cases studied showed predominance of male (68.65%). Maximum cases were in the age group of 21 to 30 years (20.14%) followed by 31 to 40 years (18.28%). The most common lesion was steatosis, accounting for 78 (30%) out of 262 liver specimens. There were 43 (16.5%) cases of congestion, 20 (7.8%) cases of hepatitis and 17 (6.5%) cases of steatohepatitis. Ten (4%) cases of cirrhosis were noted.

Conclusions: The present study showed that Histological analysis of liver is important learning objective for pathologists and a significant role in ascertaining the cause and manner of death.

Keywords: Medicolegal cases; Tertiary care centre; Liver; Steatosis; Cirrhosis.

Author Affiliation: ¹Resident Doctor, Department of Pathology, ²Professor and Head, Department of Pathology, Dr. Shankarrao Chavan Government Medical College & Hospital, Nanded, Maharashtra 431606, India, ³Associate Professor and Head, Department of Pathology, Government Medical College, Parbhani, Maharashtra 431401, India.

Corresponding Author: Shrinivas Bharat Borkar, Resident Doctor, Department of Pathology, Dr. Shankarrao Chavan Government Medical College & Hospital, Nanded, Maharashtra 431606, India.

E-mail: drshriborkar.sb@gmail.com

Received on: 13.03.2024 Accepted on: 16.04.2024



This work is licensed under a Creative Commons Attribution-NonCommercial-ShareAlike 4.0.

INTRODUCTION

The importance of silent liver disease in the overall perspective of pathology and clinical medicine cannot be over emphasized.¹ Liver is vulnerable to a variety of metabolic, toxic, microbial and circulatory insults. Sometimes, the disease is primary while in others the hepatic involvement is secondary to cardiac decompensation, alcoholism

or extrahepatic infections.² The underlying causes of chronic liver diseases vary in different geographic areas and are based on various factors such as socioeconomic status, life style, diet, local or regional infections, and other endemic diseases.³ The major primary diseases of liver are circulatory disturbances, hepatic steatosis, alcoholic liver diseases and neoplasms.⁴

SUBJECTS AND METHODS

Study design

The present study is a retrospective observational study with 292 medicolegal autopsy cases received over a one-year period from November 2022 to October 2023 conducted in the Department of Pathology of a tertiary care centre. Thirty specimens were excluded on account of extensive autolysis. Hence the study included 262 cases. Representative tissue from macroscopically variable areas of a liver was collected in a 10% neutral buffered formalin in the autopsy room. For histopathological analysis, specimens from all of the medicolegal cases were fixed in a 10% neutral buffered formalin solution. Haematoxylin and eosin (H&E) stains were used to stain each section. The weights of all visceral organs were recorded during the autopsy, and then, sections were examined histologically by the Department of Pathology. Gross and histopathological features were studied, and incidental and interesting findings were noted in a brief discussion.

Inclusion and exclusion criteria

The sample included all medicolegal autopsy cases except extensive autolyzed specimens.

RESULTS

A total of 262 cases were taken in this study with a range of 10-80 years, with male preponderance. The most common histopathology of the cases was seen in the age group 31-40 years (81 cases, i.e. 30.9%). Number of males was 175 (66.79%) much higher than females (87 cases, 33.20%) with male:female ratio of 2.01: 1. Various lesions encountered in the study and their prevalence is presented in Table 1. The most common lesion was steatosis (fatty change) seen in 79 (33.2%) cases affecting 61 males and 18 females.

Table 1: Gender wise distribution of autopsy cases (n=262)

Gender	No. of cases	Percentage
Male	175	66.79
Female	87	33.21
Total	262	100

Table 2: Age wise distribution of autopsy cases (n=262)

Age group (years)	Male	Female	Total (%)
20-10	23	11	34 (12.9)
21-30	40	19	59 (22.51)
31-40	35	17	52 (19.84)
41-50	30	15	45 (17.17)
51-60	24	11	35 (13.35)
61-70	19	9	28 (10.68)
71-80	4	3	09 (3.43)
Total	175	87	262

Table 3: Showing histopathological findings of liver and their prevalence

Histopathological Findings	Cases	Percentage
Steatosis	79	30.15
Congestion	46	17.55
Nonspecific lesion	77	29.38
Hepatitis	21	8.01
Nonspecific reactive hepatitis	14	5.3
Ischemic hepatitis	5	1.9
Acute hepatitis	2	0.7
Steatohepatitis	18	6.87
Cirrhosis	11	4.19
Microabscesses	7	2.67
Hepatic Granuloma	2	0.76
Total	262	100

All cases showed macrovascular steatosis. History of alcohol consumption was available in 17 males. Congestion was seen in 46 (17.5%) cases affecting 23 males and 20 females. We had total 21 (7.8%) cases of hepatitis, including 14 cases of nonspecific reactive hepatitis, 5 cases of ischemic hepatitis and 2 cases of acute hepatitis. There were

18 (6.8%) cases of steatohepatitis characterized by ballooning degeneration of hepatocytes, pericellular polymorphonuclear infiltrate and chicken wire fibrosis. Only two males with steatohepatitis had history of chronic alcoholism. 11 (4%) cases of cirrhosis were seen affecting 7 males and 3 females.

History of alcohol consumption was present in two males. We had 7 (2.6%) cases of micro abscesses and 2 (0.76%) cases of hepatic granulomas. There was one case of sickle cell anaemia. The rest of the case 77 were of non-specific lesions.

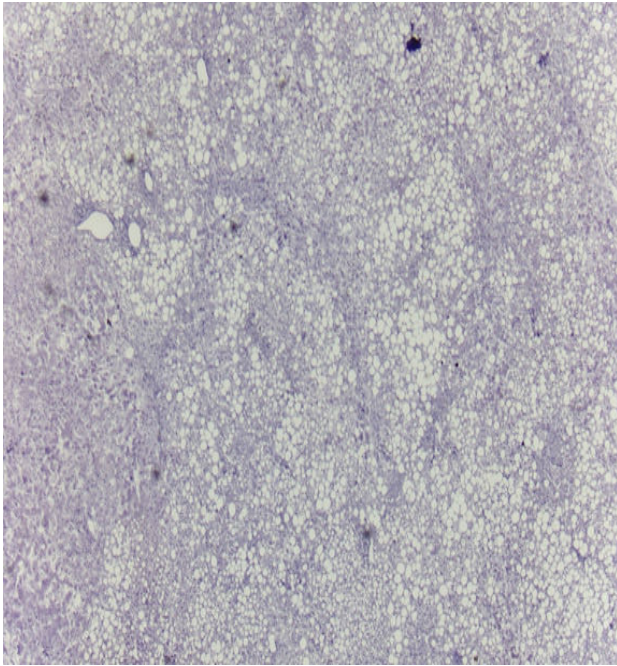


Fig. 1: Photograph showing Fatty liver (H & E, 10x).

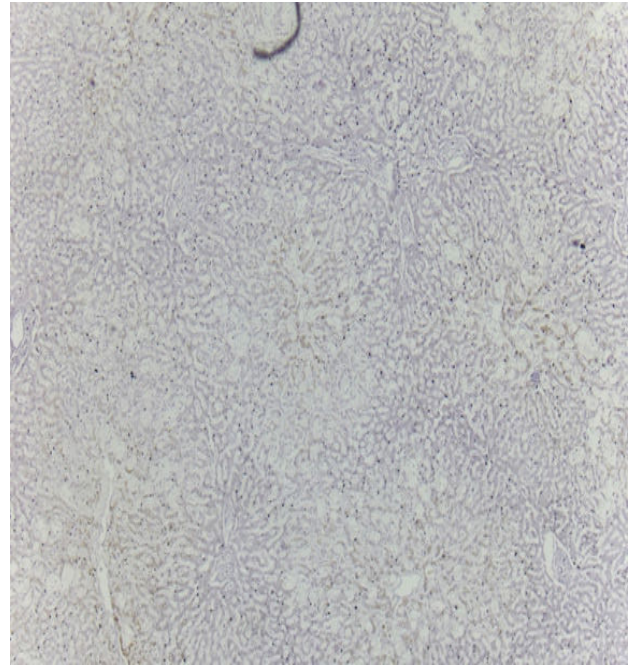


Fig. 2: Photograph showing CVC Liver (H & E, 10x).

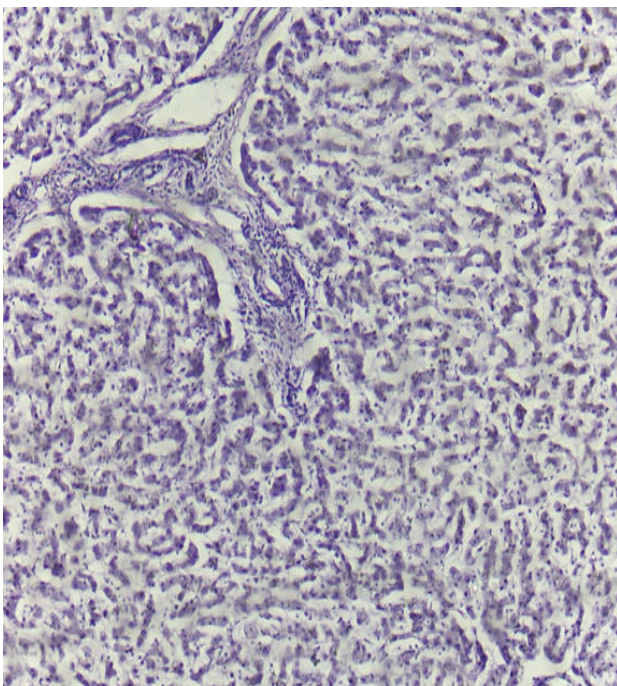


Fig. 3: Photograph showing Chronic Hepatitis (H & E, 10x).

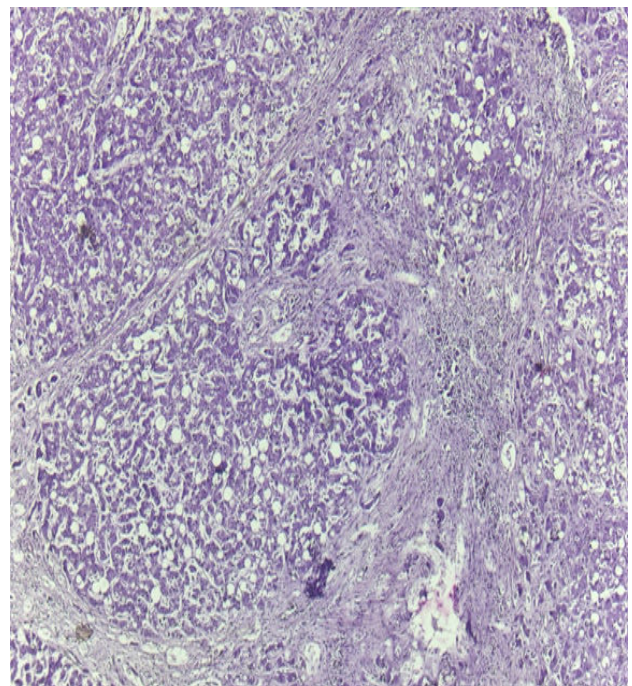


Fig. 4: Photograph showing Cirrhosis of Liver (H & E, 10x).

DISCUSSION

Determining the cause of death and understanding its pathogenesis are both aided by medicolegal autopsy studies. The causes of many liver diseases are well established. Regular intake of alcohol between 40-80 gm increases the liver weight and frequency of fatty changes in liver.⁵ Three pathologically evident liver disorders are typically caused by excessive alcohol consumption: fatty liver, hepatitis, and alcoholic cirrhosis. Any of the three may occur simultaneously in the same patient or even all three. Clinicians must have a high index of suspicion because significant liver disorders might be asymptomatic and may not be detected until death. Therefore, it is critical that clinicians precisely assess the liver's functioning condition in order to aptly identify the disease for effective treatment.

The present study is focused on the liver lesions through autopsies in 262 medicolegal cases at a tertiary care centre, revealing a diverse range of histopathological findings of liver across specific and non-specific lesions in cases of different ages and gender. The mean age group of the cases were seen in the age group 31-40 years, with an average age range spanning from 10-80 years. Notably male cases were more prevalent than female cases, a trend that is similar to previous studies such as one conducted by Singal P et al¹, Patel PR et al² and Bhagat R et al⁴. In the present study maximum number of cases (38.42%) were in the age group of 21 to 30 years and 31 to 40 years. Similarly, predominance of cases in the age group of 31 to 40 years was found by Patel PR et al² and Porwal V et al.³ Fatty liver was the commonest finding in most of the studies, and our findings compare well with those of Singal P et al,¹ Patel P R et al,² Bhagat R et al,⁴ Selvi et al⁵ and Alagarsamy et al.⁶

Circulatory disruption like right sided cardiac decompensation leads to passive congestion of the liver. The liver is slightly enlarged, tense and cyanotic, with roughened edges. Microscopically there is congestion of centrilobular sinusoids. including acute and chronic congestion were seen in a significant number of cases comparable to the findings of Singhal et al. Porwal V et al had a much higher incidence. Most of the studies have commonly reported congestion in autopsied livers, probably as a terminal event, in otherwise normal histology. The microscopic evaluation of cirrhosis is essential to identify the underlying aetiology and mechanism of fibrosis leading to cirrhosis, as it is the end result of variety of liver pathology, criteria

indicating cirrhosis in decreasing order are nodules surrounded by septate with or without portal and central canal, hepatic vein tributaries in contact with fibrous septa, connective tissue septa linking central with portal canals, irregularity of architecture.⁷

This study had total 21 cases of hepatitis, including 14 cases of nonspecific reactive hepatitis, 05 cases of ischaemic hepatitis and 02 cases of acute hepatitis. Nonspecific reactive hepatitis has no uniform zonal distribution of the parenchymal changes and only some portal tracts are involved. Variable chronic inflammatory cell infiltrate with predominance of lymphocytes is found in involved portal tracts. The limiting plate is intact. Foci of liver cell necrosis, which may involve only few hepatocytes or several liver cell plates are include in parenchymal changes. Surrounding these foci, there is accumulation of lymphocytes and macrophages.

The most important features of steatohepatitis i.e. ballooning degeneration of hepatocytes, inflammatory infiltrate and pericellular fibrosis were seen in 18 (6.87%) cases.¹⁴ Mallory-Denk bodies were however not seen in any of the cases. Most common causes of steatohepatitis are alcoholic liver disease (ALD) and non-alcoholic fatty liver disease (NAFLD). There is a significant difference in the prevalence of steatohepatitis in different studies. In the present study 18 (6.87%) cases of steatohepatitis were observed, while Umesh BR et al. reported steatohepatitis in 37 (32.2%) out of 105 cases.

CONCLUSION

Autopsy based studies are useful in estimating the prevalence of liver diseases which are often asymptomatic till late in the course of disease. Histopathological study of liver specimens enables to diagnose primary liver diseases like hepatitis, steatohepatitis and cirrhosis. Steatosis was the most frequently encountered lesion in this study.¹²

Histological examination of the liver specimens at autopsy is an important learning tool for pathologists as well as clinicians to study silent liver diseases. Silent diseases of the liver are not uncommon. Steatosis is the most common finding but inflammatory disorders comprise a significant minority.⁸ Liver autopsy studies can thus improve diagnostic and clinical approach towards liver diseases.

From our study we concluded that incidence of liver diseases was more common in males. Most affected age group was between 21 to 30 years (22.51%) followed by 31 to 40 years. Steatosis

(30.15%) was the most common histological finding. Most of the cases with steatosis had a history of chronic alcohol consumption, which indicates that alcohol is a major culprit in the pathogenesis of fatty liver.⁹ Hence, awareness about adverse effects of alcohol use is necessary in the community. Other major histological findings were congestion (26.49%) followed by cirrhosis (4.19%).

Conflict of Interest: None

ACKNOWLEDGEMENT

I would like to express my deepest appreciation to my family for their support and love and I am extremely grateful to my head of department, guide and assistant professor for guiding me to complete my paper, this would not have been possible without their guidance, support and nurturing.

REFERENCES

1. Bhagat R, Singh S, Kumar V. Histopathological Spectrum of Liver Diseases in Autopsy Cases. Tuberculosis. 2019;7(7):467-71. doi:10.18535/jmscr/v7i7.85.
2. Singal P, Kaur M, Deepika. Incidental Findings in Autopsy Examination of Liver: A Study of 70 Cases. Ann Int Med Den Res. 2017;3(3):30-2.
3. Patel PR, Patel R, Tailor H et al. Incidental Findings in Autopsy examination of liver: a study at tertiary care hospital. International journal of community Medicine and Public Health 2016;3(30):697-99.
4. Porwal V, Jain D, Khandelwal S, Gupta S, Rathi A. Spectrum of Liver Pathology in Autopsy Cases: A Study at Ajmer. Ann Pathol Lab Med. 2018;5.
5. Selvi RT, Selvam V, Subramaniam PM. Common Silent Liver Disease In and Around of Salem Population: An Autopsy Study. Journal of Clinical and Diagnostic Research 2012;6(2):207-10.
6. Alagarsamy J, Muthureddy Y, Yadav N. Incidentally Discovered Liver Diseases – An Autopsy Study of Fifty Cases. International Journal of Science and Research (IJSR) 2014;3(5):1330-32.
7. The value of histological examination in the audit of hospital autopsies: a quantitative approach. Zaitoun AM, Fernandez C. Pathology. 1998;30:100-104. [PubMed] [Google Scholar]
8. A comprehensive review of pathological examination in forensic medicine: past, present, and future. Singh D, Tiwari RC, Kumar A, et al. Cureus. 2022;14:0. [PMC free article] [PubMed] [Google Scholar]
9. Majethia NK, Patil MV, Kalgutkar AD. A Histopathological Study of Liver in 118 Cases of Cirrhosis. J Liver. 216;5(1). doi:10.4172/2167-0889.1000193.
10. Pathological findings in liver autopsy. Bal MS, Singh SP, Bodal VK, Oberoi SS, Surinder K. J Indian Acad Forensic Med. 2004;26:55-57. [Google Scholar]
11. Silent liver diseases in autopsies from forensic medicine of Tehran. Sotoudehmanesh R, Sotoudeh M, Ali-Asgari A, et al. <https://pubmed.ncbi.nlm.nih.gov/17061603/> Arch Iran Med. 2006;9:324-328. [PubMed] [Google Scholar]
12. Prevalence of lung lesions at autopsy: a histopathological study. Khare P, Gupta R, Ahuja M, Khare N, Agarwal S, Bansal D. J Clin Diagn Res. 2017;11:0-6. [PMC free article] [PubMed] [Google Scholar]
13. Bal MS, Singh SP, Bodal VK. et al., Pathological Findings in Liver Autopsy. Journal of Indian Academy of Forensic Medicine 2004;26(20):55-57.
14. Kakar S, Gill RM. Nonneoplastic liver disease. In: Mill SE, Greenson JK, Homick JL, Longacre TA, Reuter VE (Eds). Sternberg's Diagnostic Surgical Pathology. Philadelphia; Wolters Kluwer Health 2015:1694.

