

## Histopathological spectrum of adrenal gland lesions

Bheemaraju Venkata Vydehi<sup>1</sup>, Nandam Mohan Rao<sup>2</sup>, Vissa Shanthi<sup>3</sup>, Byna Syam Sundara Rao<sup>4</sup>, Grandhi Bhavana<sup>5</sup>, Amulya Boddapati<sup>6</sup>

<sup>1,2,4</sup>Professor <sup>3</sup>Professor & Head <sup>5</sup>Associate Professor <sup>6</sup>Assistant Professor, Department of Pathology, Narayana Medical College, Nellore, Andhra Pradesh 524004, India.

### Abstract

*Introduction:* Suprarenal gland is a bipartite endocrine gland which is divided into adrenal cortex and adrenal medulla. Histopathological spectrum of adrenal lesions consist of adrenal cysts, adrenal myelolipoma, adrenal cortical adenoma, adrenal cortical carcinoma and pheochromocytoma.

*Aims and objectives:* To study the histopathological spectrum of adrenal lesions diagnosed at Narayana Medical College & Hospital, Nellore for over a period of two years.

*Materials and methods:* All the adrenal gland specimens submitted to the Department of Pathology, Narayana Medical College and Hospital, Nellore, from January 2016 to December 2017 were included in the study. Adrenalectomy specimens were fixed in 10% formalin, subjected to routine processing, embedding, cutting and then stained with Haemotoxylin and Eosin staining technique.

*Results:* A total of 18 cases were noticed in the present retrospective study. Most of the tumors were noted in the age group of 21-40 years with female predominance. Most common adrenal lesion noted in our study was pheochromocytoma (55.55%).

*Conclusion:* We diagnosed a total of 18 cases of adrenal lesions including adrenal cysts, adrenal cortical tumors and adrenal medulla tumors. Most of the adrenal tumors were noted in the age group of 21-40 years with female predominance. Most common adrenal lesions noted was pheochromocytoma.

**Keywords:** Adrenal Cysts; Adrenal Myelolipoma; Adrenal Cortical Tumors; Pheochromocytoma.

### Corresponding Author:

**Nandam Mohan Rao**, Professor,  
Department of Pathology, Narayana Medical  
College, Nellore, Andhra Pradesh 524004,  
India.

E-mail: [nmr2020kmc@gmail.com](mailto:nmr2020kmc@gmail.com)

Received on 13.12.2018,

Accepted on 24.12.2018

### How to cite this article:

Bheemaraju Venkata Vydehi, Nandam. Mohan Rao, Vissa Shanthi et al. Histopathological spectrum of adrenal gland lesions. Indian J Pathol Res Pract. 2019;8(1): 11-15.



## Introduction

Suprarenal gland is a bipartite endocrine gland which is divided into adrenal cortex and adrenal medulla having different development, structure and function.

Adrenal cortex arises from mesoderm and produces steroid hormones. Adrenal medulla arises from neural crest and produces catecholamines. In the present retrospective study, 18 cases of histopathological spectrum of various adrenal lesions were noted during the period of January 2016 to December 2017.

## Materials and Methods

The present retrospective study was carried out in the Department of Pathology, Narayana Medical College and Hospital, Nellore, a tertiary care Hospital. All the adrenal gland specimens received during the period from January 2016 to December 2017 were included in the present retrospective study. All the adrenal specimens were fixed in 10% formalin for 24 hours. Each specimen was grossed thoroughly. Representative bits were taken, subjected to routine processing, embedding in paraffin, cutting, staining with routine Hematoxylin and Eosin stains. Histopathological spectrum of various adrenal lesions were noted.

## Results

Out of 18 cases of adrenal lesions, male:female ratio is 0.8:1. Mean age of total adrenal lesions were 35.5 years. Out of 18 cases of adrenal lesions, 8 cases (44.44%) were diagnosed at right adrenals and 10 cases (55.56%) were diagnosed at left adrenals. Adrenal lesions were more predominant in left adrenal. Out of 18 cases of adrenal lesions, 2 cases (11.11%) were incidentally diagnosed on ultrasound scanning, flank pain noted in one case (5.55%), hypertension noted in 8 cases (44.44%), hirsutism noted in 5 cases (27.78%), and muscle cramps noted in 2 cases (11.11%) (Table 1).

**Table1:** Mean age, Sex ratio, Laterality and clinical characteristics of adrenal lesions

Mean age	35.5 years
Male to female (M:F) ratio	8:10 (0.8:1)
Laterality	
Right	8 (44.44%)
Left	10 (55.56%)
Clinical presentation	

Asymptomatic (incidental finding)	2 (11.11%)
Flank pain	1 (5.55%)
Hypertension	8 (44.44%)
Hirsutism	5 (27.78%)
Muscle cramp	2 (11.11%)

Out of 18 cases of adrenal lesion, one case (5.55%) was noted in 0-10 years age group, 2 cases (11.11%) were noted in 11-20 years age group, 3 cases (16.67%) were noted in 21-30 years age group, 6 cases (33.33%) were noted in 31-40 years age group, 3 cases (16.67%) were noted in 41-50 years age group, and 3 cases (16.67%) were noted in 51-60 years age group. Most of the adrenal lesions (50%) were noted in 21-40 years age group (Table 2).

**Table 2:** Age group distribution of adrenal lesions

Sl. No.	Age group	Number of cases	Percentage
1.	0-10	1	5.55%
2.	11-20	2	11.11%
3.	21-30	3	16.67%
4.	31-40	6	33.33%
1.	41-50	3	16.67%
2.	51-60	3	16.67%
	Total	18	100%

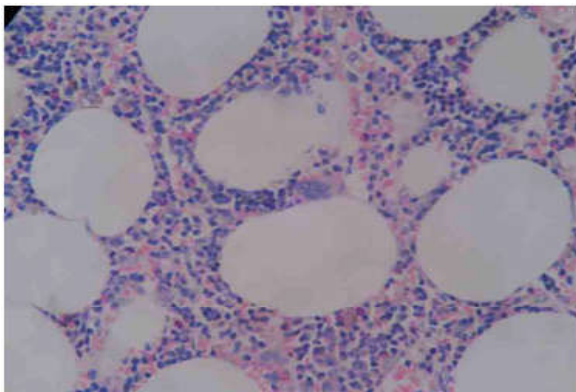
Out of 18 cases of adrenal lesions 2 cases (11.11%) were non- neoplastic lesions and 16 cases (88.89%) were neoplastic lesions. Out of 2 (11.11%) cases of non neoplastic lesion, one case (5.55%) was epithelial cyst of adrenal was noted in the 0-10 years age group who is 8 years male patients, one case (5.55%) was pseudocyst of adrenal noted at the 31-40 years age group who is 35 years male patient. Out of 16 cases (88.89%) of neoplastic lesions, 2 cases (11.11%) were pheochromocytoma noted in the age group of 11-20 years which are 12 years and 20 years occurring in male patients. 3 cases (16.67%) were pheochromocytoma noted in the age group of 21-30 years which are 26 years male patient, 26 years female patient and 30 years male patient. 5 cases (27.78%) of neoplastic lesions occurred in the age group of 31-40 years, 2 (11.11%) cases were adrenal cortical carcinoma which occurred in 35 years female patient and 38 years female patient, one case was pheochromocytoma occurring in 31 years female patient, and two cases were adrenal cortical adenoma which occurred in 40 years female patient. 3 cases (16.67%) of neoplastic lesions occur in the age group of 41-50 years, 2 cases were pheochromocytoma which occur in 42 years female patient and 50 years female patient, and one case was adrenal myelolipoma which occurred in 50 years male patient. 3 cases (16.67%) of neoplastic

lesions occurred in the age group of 51-60 years, 2 cases were pheochromocytoma which occurred in 51 years male patient and 52 years female patient, and one case was adrenal cortical carcinoma which occurred in 53 years male patient (Table 3).

**Table 3:** Age group distribution of non neoplastic adrenal lesions and neoplastic lesions

Sl. No.	Age group (in years)	Number of cases	Percentage
<b>A. Non neoplastic lesions</b>			
1.	0-10	1	5.55%
2.	11-20	-	-
3.	21-30	-	-
4.	31-40	1	5.55%
<b>B. Neoplastic lesions</b>			
1.	0-10	-	-
2.	11-20	2	11.11%
3.	21-30	3	16.67%
4.	31-40	5	27.78%
5.	41-50	3	16.67%
6.	51-60	3	16.67%
	Total	18	100%

Out of 18 cases of adrenal lesions one case (5.55%) was epithelial cyst, one case (5.55%) was pseudocyst, one case (5.55%) was adrenal myelolipoma (Fig. 1), 2 cases (11.11%) were adrenal cortical adenoma, 3 cases (16.67%) were adrenal cortical carcinoma and 10 cases (55.55%) were pheochromocytoma (Fig. 2) Out of 18 cases of adrenal lesions, pheochromocytoma (55.55%) was most common adrenal lesion (Table 4).

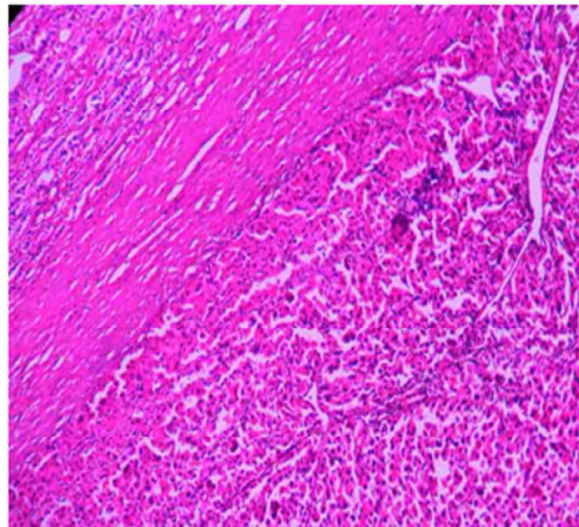


**Fig. 1:** Photo microscopic picture of adrenal myelolipoma (H&E, 400X)

**Table 4:** Histopathological spectrum of adrenal lesions.

Sl. No.		Number of cases	Percentage
<b>A. Non neoplastic lesions</b>			
1.	Epithelial cyst	1	5.55%
2.	Pseudocyst	1	5.55%

<b>B. Neoplastic lesions</b>			
1.	Adrenal myelolipoma	1	5.55%
2.	Adrenal cortical adenoma	2	11.11%
3.	Adrenal cortical carcinoma	3	16.67%
4.	Pheochromocytoma	10	55.55%
	Total	18	100%



**Fig. 2:** Photo microscopic picture of pheochromocytoma (H&E, 400X)

**Discussion**

An adrenal gland lesions consist of non-neoplastic lesions and neoplastic lesions. In non-neoplastic lesion, cystic lesions of adrenal are common. Neoplastic lesions are mainly two types. 1. Benign neoplasms 2. Malignant neoplasms. WHO histological classification of tumors of the adrenal glands are mainly five types.

1. Adrenal cortical tumors -
  - a. Adrenal cortical adenoma.
  - b. Adrenal cortical carcinoma.
2. Adrenal medullary tumors -
  - a. Benign pheochromocytoma/ paraganglioma.
  - b. Malignant pheochromocytoma.
  - c. Mixed tumors.
  - d. Composite pheochromocytoma.
3. Extra adrenal paraganglioma.
4. Other adrenal tumors -
  - a. Adenomatoid tumor.

- b. Sex-cord stromal tumor.
  - c. Soft tissue and germ cell tumor.
  - d. Teratoma.
  - e. Myelolipoma.
  - f. Schwannoma.
  - g. Ganglioneuroma.
  - h. Angiosarcoma.
5. Secondary tumors.

According to Geroge et al. study, 1-5% of the adrenal tumors were incidental finding. Prevalence of adrenal tumors during autopsy was 2-9% and pheochromocytoma was the most common adrenal tumor [1]. According to David Arnaol et al study, incidence of adrenal masses found on abdominal CT scans was between 0.6% and 1.3% where as the incidence of adrenal masses on thoracic CT scan, abdominal CT scan and pelvic CT scan was between 0.4% and 4% [2]. Suprarenal gland lesions can exhibit wide spectrum of clinical manifestations due to local mass effects such as flank pain, hematuria, and palpable lump, or due to production of hormones such as hypertension, palpitation, headache, muscle cramps and hirsutism. In our study majority of adrenal lesions exhibiting various clinical transifestations such as flank pain, hypertension, hirsutism and muscle cramps. In the present retrospective study, out of 18 cases, 2 cases of adrenal tumors were incidentally detected. According to the internet sources mean age of adrenal lesions was 44 years. In the present retrospective study mean age of adrenal lesions was 35.5 years.

According to available statistics, pheochromocytoma incidence is 2 to 8 per million persons per year. In the present retrospective study, out of 18 cases, 10 cases (55.55%) were pheochromocytoma of which 2 cases were incidentally detected. According to Manger et al study, 50% of the pheochromocytomas were detected at autopsy [3]. According to Cohen DL et al. study, good number of patients with histologically diagnosed pheochromocytomas were lacking clinical symptoms [4]. Histopathological examination of pheochromocytoma reveal solid pattern, nesting pattern and Zell ballen pattern of polygonal to spindled shaped tumor cells showing stippled nuclear chromatin and granular cytoplasm. Haemorrhagic areas noted due to highly vascular tumor.

Most common benign neoplasm of adrenal gland is adrenal adenoma. According to Julie H Song et al. study, 75% of the adrenal masses were adrenal adenoma [6]. In the present retrospective study, 2 cases of adrenal adenoma were reported which is

about 11.11%. There is a discrepancy between Julie H Song et al. study and our study due to low sample size of our study. Histopathological examination of adrenal cortical adenoma reveal capsulated tumor tissue showing solid pattern, glandular pattern of round to polygonal abundant cells having round, central bland nuclei with abundant vacuolated cytoplasm to esonophilic cytoplasm. No capsular invasion or non vascular invasion are noted.

Adrenal myelolipoma is a very rare tumor with extramedullary hematopoiesis. Extramedullary hematopoiesis common sites are liver and spleen, may also occur in adrenal glands, breast, duramater and bowel [6,7,8,9]. According to Banerji JS et al. study, one case of extramedullary hematopoiesis in adrenal gland was noted incidentally [10]. In the present retrospective study, one case of adrenal myelolipoma was noted. Histopathological examination of a adrenal myelolipoma reveal sheets, clusters of mature adipocytes and haemotopoietic elements noted in adrenal parenchyma.

According to Abeshouse GA et al. study, incidence of the adrenal cyst are 4%-22% [11]. According to origin, cystic lesions are mainly 4 types, endothelial cysts (most common) 45%, epithelial cysts 9%, pseudocyst/hemorrhagic cyst 39% and parasitic cysts 7%. In our study incidence of adrenal cysts are 11.11% which is similar to Abeshouse GA et al. study [11]. In our study, one case (5.55%) of epithelial cyst and one case (5.55%) of pseudocyst are noted. Histopathological examination of endothelial cyst reveal fibrous cyst wall inner surface focally lined by flattened cells resembling normal endothelium. Histopathological examination of epithelial cyst reveal cyst lined by single layer of cytokeratin positive epithelial cells.

Histopathological examination of hemorrhagic cysts/pseudocyst reveal hyalinised fibrous capsule containing nests of entrapped adrenal cortical cells and amorphous cyst contents composed of mixture of serum, blood and fibrin. Histopathological examination of parasitic cyst similar to hydatid cyst.

According to Neri and Nance study incidence of adrenal cortical carcinoma were 7% [12]. In our study incidence of adrenal cortical carcinomas were 16.67% which is higher than the Neri and Nance study [12]. Histopathological examination of adrenal cortical carcinoma reveal capsulated tumor tissue showing solid sheets of round to polygonal cells having marked pleomorphic nuclei, prominent nucleoli, increased nuclear, cytoplasm ratio, and nucleoli, abundant vacuolated cytoplasm to eosinophilic cytoplasm. Within the tumor

tissue plenty of atypical mitotic figures are noted. Capsular invasion and vascular invasion of tumor tissue are noted. Necrotic areas are also noted.

### Conclusion

We diagnosed a total of 18 cases of histopathological spectrum of adrenal lesions consisting of adrenal cysts, adrenal cortical tumors and pheochromocytoma. Most of the adrenal tumors were diagnosed in the age group of 21-40 years with female predominance. In our study, most common adrenal lesions was pheochromocytoma.

### References

1. George T Griffing. Adrenal Incidentaloma: Background, Anatomy, Pathophysiology. *emedicine. medscape. com/article/116587 - Overview.*
2. David T Arnol, Jennifer Blumoff Reed, Kristina Burt. Evaluation and management of the incidental adrenal mass. *Proc (Bayl Univ Med Cent), 2003; 16(1):7-12.*
3. Manger WM. An overview of pheochromocytoma: history, current concepts, vagaries, and diagnostic challenges. *Ann NY Acad Sci. 2006;1073:1-20.*
4. Cohen DL, Fraker D, Townsend RR. Lack of symptoms in patients with histologic evidence of Pheochromocytoma. *Ann NY Acad Sci. 2006;1073: 47-51.*
5. Julia H. Song, Fakhra S. Chaudhry, William W. The Incidental Adrenal Mass on CT: Prevalence of Adrenal Disease in 1049 consecutive Adrenal Masses in patients with no known malignancy. *AJR Am J Roentgenol. 2008;190(5):1163-8.*
6. Sharon D, Lau KK, Lau T, Bowden DKJ. Extramedullary hematopoiesis: a pictorial review of its typical and atypical locations. *Med. Imaging Radiat. Oncol. 2012;56:538-44.*
7. Boucher A, Puech P, Kharroubi D, Boyer T, Lefèvre G. Renal extramedullary hematopoietic tumor revealing a hereditary spherocytosis in an adult patient. *Charpentier. Rev. Med. Interne. 2015;36: 848-53.*
8. Karami H, Kosaryan M, Taghipour M, Sharifian R, Aliasgharian A, Motalebi M. Extramedullary hematopoiesis presenting as a right adrenal mass in a patient with beta thalassemia. *Nephrourol. Mon. 2014;5(6):e19465.*
9. Azarpira N, Heidari Esfahani M, Paydar S. Extramedullary hematopoiesis in adrenal gland: an uncommon cause of adrenal incidentaloma in sickle cell disease. *Iran J. Pediatr. 2014;24:784-86.*
10. Banerji JS, Kumar RM, Devasia A. Extramedullary hematopoiesis in the adrenal: Case report and review of literature. *Can Urol Assoc J. 2013;7(5- 6): E436-E438.*
11. Abeshouse GA, Goldstein RB, Abeshouse BS. Adrenal cysts: review of the literature and report of three cases. *J Urol. 1959;81(6):711-9.*
12. Neri LM, Nance FC. Management of adrenal cysts. *Am Surg. 1999;65(2):151-63.*